

Antegrade Hypogastric Revascularization During Endovascular Aortoiliac Aneurysm Repair: An Alternative to Bilateral Embolization

Renato A. Mertens, Michel P. Bergoing, Leopoldo A. Mariné, Francisco Valdés, and Albrecht H. Krämer, Santiago, Chile

Anatomy has been the major challenge to overcome to increase safe and durable applicability of endografting for the treatment of abdominal aortic aneurysm. Bilateral iliac aneurysm preventing an appropriate distal landing zone for the endograft is a common condition and can be managed by (a) increasing the diameter of the endograft, with limitations in available sizes, (b) bilateral hypogastric embolization, accepting an increased morbidity, (c) the use of a branched device, increasing the cost and currently with limited availability, (d) combined surgical hypogastric revascularization by the retroperitoneal approach, or (e) retrograde revascularization from the ipsilateral external iliac artery using an endograft. We describe the use of widely available devices to obtain stable antegrade revascularization of one hypogastric artery during aortic endografting. We report the case of a 68-year-old man, at high risk for an open procedure, who presented with bilateral iliac aneurysm and minor aortic ectasia; no iliac landing zone was available. A regular bifurcated graft was deployed and extended into one of the external iliac arteries, preceded by ipsilateral hypogastric embolization. Through an upper extremity approach, an endograft was deployed from the remaining bifurcated graft branch into the other hypogastric artery, followed by ipsilateral external iliac occlusion. Finally a femorofemoral crossover bypass was performed. The patient recovered event free, and patency of the endograft and absence of endoleak were demonstrated on computed tomography. Minor unilateral buttock claudication resolved in 6 weeks and sexual function was preserved. This technique is a reasonable alternative to consider in the endovascular treatment of patients with bilateral iliac aneurysm, allowing preservation of pelvic perfusion, limiting cost, and using available devices.

INTRODUCTION

Endografting has become a major treatment option of abdominal aortic and iliac aneurysm.¹ Anatomy is probably the major challenge to overcome to ensure safe and durable applicability of this technology. Iliac aneurysmal degeneration is commonly associated with aortic aneurysms. Commercially available devices can obtain a proper distal seal in dilated common iliac arteries up to 22 mm. When bilateral

common iliac aneurysms are present, multiple options to deal with this situation have been described, including bilateral hypogastric occlusion associated with extension of the endograft into the external iliac arteries, accepting variable morbidity related to pelvic ischemia. Other alternatives, including unilateral hypogastric revascularization, have been described,²⁻⁸ but they all have limitations related to the technique itself, cost, or availability.

We describe an alternative of pelvic revascularization during aortic endografting using commercially available devices.

CASE REPORT

A 68-year-old obese male patient presented with bilateral iliac aneurysms, 3.8 and 4.7 cm in diameter on the

Departamento de Cirugía Vascular y Endovascular, División de Cirugía, Pontificia Universidad Católica de Chile, Santiago, Chile.

Correspondence to: Renato A. Mertens, MD, 3990 Apoquindo, Suite 601, Las Condes, Santiago, Chile, E-mail: rmertens@med.puc.cl

Ann Vasc Surg 2010; 24: 255.e9-255.e12

DOI: 10.1016/j.avsg.2009.07.009

© Annals of Vascular Surgery Inc.

Published online: November 9, 2009

right and left side, respectively, with extension into the right hypogastric artery. His previous history was significant for hypertension, former heavy smoker, and a myocardial infarction. There was no available landing zone for a regular bifurcated endograft at the common iliac arteries (Fig. 1).

Under epidural anesthesia, vascular access was obtained through bilateral common femoral artery surgical exposures. The left femoral artery was used to introduce and completely deploy a regular bifurcated Zenith endograft (Cook Medical, Bloomington, IN). Proximal left brachial access was obtained through a small surgical exposure and a 10 Fr×80-cm-long sheath was introduced and localized at the left branch of the bifurcated graft. The left hypogastric artery was selectively catheterized and an Amplatz 1-cm soft-tip guidewire (Boston Scientific, Natick, MA) was used as support to advance a 13.5×120 mm Fluency endograft (Bard Peripheral Vascular, Covington, GA) (Fig. 2A). The endograft was deployed into the hypogastric artery with a 3-cm overlap at the artery and the Zenith endograft, obtaining a complete seal (Fig. 2B). Next, an Amplatzer Vascular Plug (AGA Medical, Plymouth, MN) was used to occlude the left external iliac artery. The right hypogastric artery was coil embolized (embolization coils; Cook Medical, Bloomington, IN) and the endograft was then extended into the external iliac artery, requiring a self-expanding stent (Smart Stent; Cordis Corporation, Bridgewater, NJ) at the distal end to obtain a smooth transition in this very tortuous artery. The procedure was completed with a femorofemoral crossover bypass using an 8-mm Dacron graft.

The patient's recovery was uneventful and had mild right buttock claudication for 6 weeks. Sexual function was preserved. A computed tomography scan showed complete exclusion of the aneurysms and patent reconstructions (Fig. 3).

DISCUSSION

Bilateral iliac aneurysms preventing an appropriate landing zone for an endograft represent a common condition and can be managed by several options.

1. The use of oversized iliac limbs up to 28 mm (Endurant; Medtronic, Santa Rosa, CA) or the distal deployment of aortic extensions allows landing on ectatic or aneurysmal common iliac arteries, obtaining sealing proximal to the hypogastric artery. This is not only limited by the available sizes but also by the concern of dilatation of the landing zone leading to endoleak.
2. Bilateral hypogastric embolization has been widely used and reported by some groups with very different results and safety. All of them agree in a variable but eventually acceptable incidence of permanent and limiting buttock claudication and impotence.^{6,9-12} Serious morbidity has also

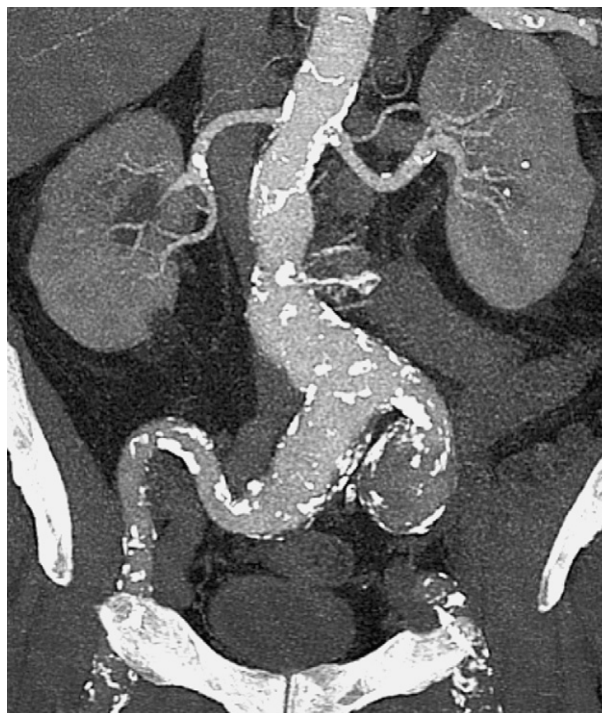

Fig. 1. Coronal reconstruction of the preoperative computed tomography scan, showing a bilateral iliac aneurysm. The high diameter of the distal common iliac arteries prevents landing of an endograft.

been described, such as bowel¹³ and skin^{14,15} necrosis.

3. A combined or hybrid approach for surgical revascularization of the hypogastric artery is an interesting option²⁻⁴ but increases the impact of the procedure on a potentially high-risk patient and can also be technically challenging.
4. Using an endograft to revascularize the hypogastric artery from the ipsilateral external iliac artery in a retrograde fashion has been described.⁵ There are some drawbacks related to this technique, mainly related to the acute angulation between the external iliac and hypogastric arteries. This makes the procedure difficult and exposes the device to an enormous stress, and there is limited and difficult access to the hypogastric artery in case a reintervention is needed.
5. The most recent development is the use of a branched device, allowing simultaneous ipsilateral revascularization of both the external and hypogastric arteries.⁶⁻⁸ This is probably a very good solution but increases the cost of treatment, requiring not only the device itself but also a separate covered stent to connect it to the hypogastric artery. Mid-term patency is acceptable,¹⁶ but availability at this point is limited. One possible

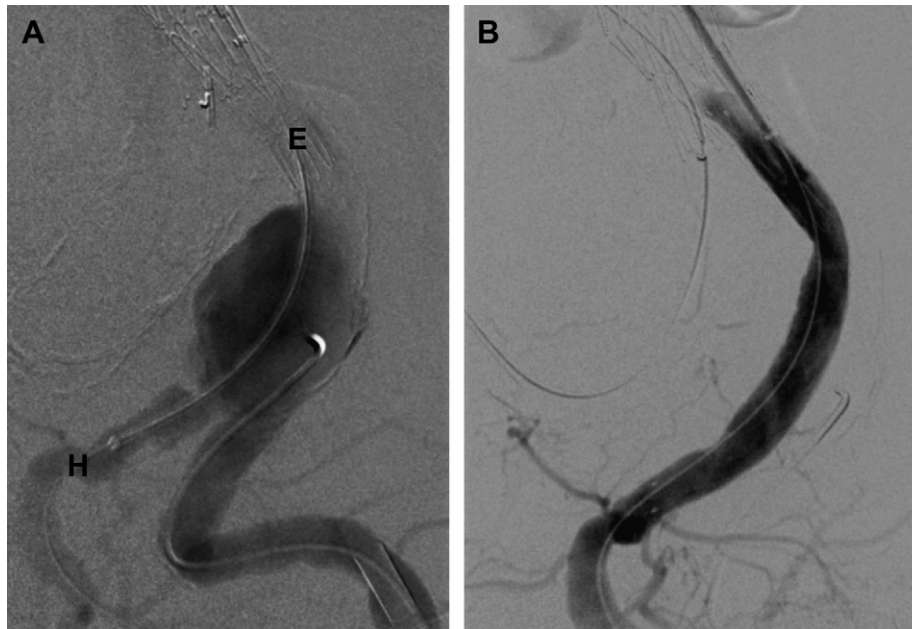


Fig. 2. (A) Angiogram before the deployment of the Fluency stent graft, from the Zenith aortic endograft (E) to the hypogastric artery (H). (B) Angiogram after deployment of the Fluency stent, showing complete sealing at both ends.

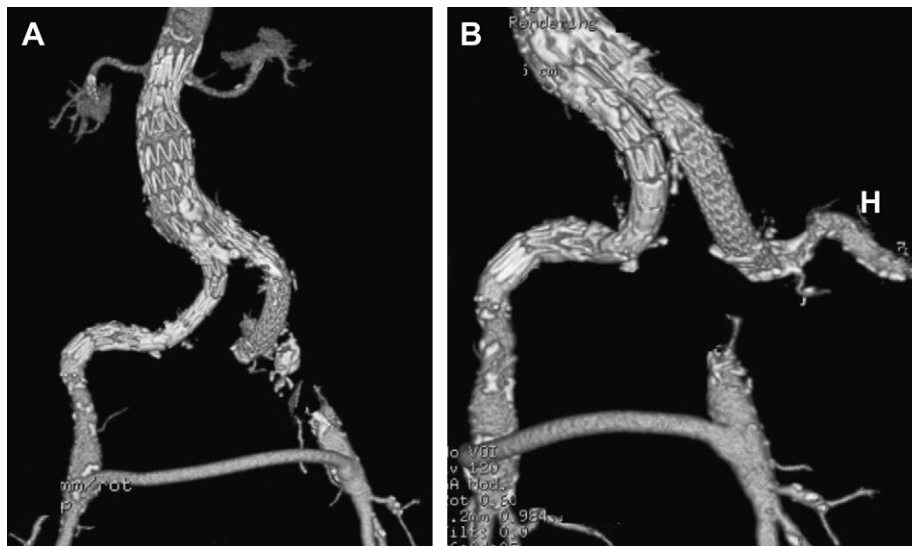


Fig. 3. Volume rendering reconstructions of a postoperative computed tomography scan, showing complete sealing, patency of all reconstructions, and flow into the left hypogastric artery (H).

advantage of this procedure over the one presented here is the use of a bifurcated graft instead of an aortouniliac approach requiring a femorofemoral crossover bypass. However, over the years, multiple reports have demonstrated the safety and durability of this extra-anatomic reconstruction in this setting.^{17,18}

The technique presented with this communication has been used by others to treat late iliac aneurysmal degeneration after open aortic aneurysm repair.¹⁹ It has also been described to preserve vascular flow to the pelvis during endografting for bilateral iliac aneurysms using different devices but a similar approach.²⁰

There are some obvious limitations to this technique, a small brachial artery size preventing access of a rather large sheath and potential diameter mismatch of available devices between different endografts, jeopardizing the long-term seal and patency. It is, however, a reasonable alternative to consider in the endovascular treatment of patients with bilateral common iliac aneurysms, allowing partial preservation of pelvic perfusion, limiting cost, and using commercially available devices.

REFERENCES

- Giles K, Pomposelli F, Hamdan A, et al. Decrease in total aneurysm-related deaths in the era of endovascular aneurysm repair. *J Vasc Surg* 2009;49:543-550.
- Unno N, Inuzuka K, Yamamoto N, et al. Preservation of pelvic circulation with hypogastric artery bypass in endovascular repair of abdominal aortic aneurysm with bilateral iliac artery aneurysms. *J Vasc Surg* 2006;44:1170-1175.
- Lee W, Nelson P, Berceci S, et al. Outcome after hypogastric artery bypass and embolization during endovascular aneurysm repair. *J Vasc Surg* 2006;44:1162-1168.
- Lee W, Berceci S, Huber TS, et al. A technique for combined hypogastric artery bypass and endovascular repair of complex aortoiliac aneurysms. *J Vasc Surg* 2002;35:1289-1291.
- Bergamini T, Rachel E, Kenney E, et al. External iliac artery-to-internal iliac artery endograft: a novel approach to preserve pelvic inflow in aortoiliac stent grafting. *J Vasc Surg* 2002;35:120-124.
- Versini F, Parlani G, Romano L, et al. Endovascular treatment of iliac aneurysm: Concurrent comparison of side branch endograft versus hypogastric exclusion. *J Vasc Surg* 2009;49:1154-1161.
- Serracino-Inglott F, Bray A, Myers P. Endovascular abdominal aortic aneurysm repair in patients with common iliac artery aneurysms: initial experience with the Zenith bifurcated iliac side branch device. *J Vasc Surg* 2007;46:211-217.
- Haulon S, Greenberg R, Pfaff K, et al. Branched grafting for aortoiliac aneurysms. *Eur J Vasc Endovasc Surg* 2007;33:567-574.
- Zander T, Baldi S, Rabellino M, et al. Bilateral hypogastric artery occlusion in endovascular repair of abdominal aortic aneurysms and its clinical significance. *J Vasc Interv Radiol* 2007;18:1481-1486.
- Wolpert L, Dittrich K, Hallisey M, et al. Hypogastric artery embolization in endovascular abdominal aortic aneurysm repair. *J Vasc Surg* 2001;33:1193-1198.
- Criado F, Wilson E, Velazquez O, et al. Safety of coil embolization of the internal iliac artery in endovascular grafting of abdominal aortic aneurysms. *J Vasc Surg* 2000;32:684-688.
- Mehta M, Veith F, Ohki T, et al. Unilateral and bilateral hypogastric artery interruption during aortoiliac aneurysm repair in 154 patients: a relatively innocuous procedure. *J Vasc Surg* 2001;33(2 suppl):S27-S32.
- Zhang W, Kulaylat M, Anain P, et al. Embolization as cause of bowel ischemia after endovascular abdominal aortic aneurysm repair. *J Vasc Surg* 2004;40:867-872.
- Lin P, Bush R, Chaikof E, et al. A prospective evaluation of hypogastric artery embolization in endovascular aortoiliac aneurysm repair. *J Vasc Surg* 2002;36:500-506.
- Lin P, Bush R, Lumsden A. Sloughing of the scrotal skin and impotence subsequent to bilateral hypogastric artery embolization for endovascular aortoiliac aneurysm repair. *J Vasc Surg* 2001;34:748-750.
- Ferreira M, Lanzotti L, Monteiro M. Iliac branched devices: technical aspects and midterm patency. *J Vasc Surg* 2009;49(1 suppl):S6-S7.
- Clouse W, Brewster D, Marone L, et al. Durability of aortouniiliac endografting with femorofemoral crossover: 4-year experience in the Evt/Guidant trials. *J Vasc Surg* 2003;37:1142-1149.
- Walker S, Braithwaite B, Tennant W, et al. Early complications of femorofemoral crossover bypass grafts after aorta uni-iliac endovascular repair of abdominal aortic aneurysms. *J Vasc Surg* 1998;28:647-650.
- Leon L, Mills J, Psalms S, et al. A novel hybrid approach to the treatment of common iliac aneurysms: antegrade endovascular hypogastric stent grafting and femorofemoral bypass grafting. *J Vasc Surg* 2007;45:1244-1248.
- Delle M, Lönn L, Wingren U, et al. Preserved pelvic circulation after stent-graft treatment of complex aortoiliac artery aneurysms: a new approach. *J Endovasc Ther* 2005;12:189-195.