

Initial Clinical Experience Using the Low-Profile Altura Endograft System With Double D-Shaped Proximal Stents for Endovascular Aneurysm Repair

Journal of Endovascular Therapy
2018, Vol. 25(3) 379–386
© The Author(s) 2018
Reprints and permissions:
sagepub.com/journalsPermissions.nav
DOI: 10.1177/1526602818771973
www.jevt.org
SAGE

Dainis Krievins, MD, PhD¹, Albrecht Krämer, MD²,
Janis Savlovskis, MD, PhD³, Georgij Oszkinis, MD, PhD⁴,
E. Sebastian Debus, MD, PhD⁵, Alexander Oberhuber, MD, PhD⁶,
and Christopher K. Zarins, MD⁷

Abstract

Purpose: To report the initial clinical results of endovascular aneurysm repair (EVAR) using the low-profile (14-F) Altura Endograft System, which features a double “D-shaped” stent design with suprarenal fixation and modular iliac components that are deployed from distal to proximal. **Methods:** From 2011 to 2015, 90 patients (mean age 72.8±8.3 years; 79 men) with abdominal aortic aneurysm (AAA; mean diameter 53.8±5.7 mm) were treated at 10 clinical sites in 2 prospective, controlled clinical studies using the Altura endograft. Outcomes evaluated included mortality, major adverse events (MAEs: all-cause death, stroke, paraplegia, myocardial infarction, respiratory failure, bowel ischemia, and blood loss ≥1000 mL), and clinical success (freedom from procedure-related death, type I/III endoleak, migration, thrombosis, and reintervention). **Results:** Endografts were successfully implanted in 89 (99%) patients; the single failure was due to delivery system malfunction before insertion in the early-generation device. One (1%) patient died and 4 patients underwent reinterventions (1 type I endoleak, 2 iliac limb stenoses, and 1 endograft occlusion) within the first 30 days. During a median follow-up of 12.5 months (range 11.5–50.9), there were no aneurysm ruptures, surgical conversions, or AAA-related deaths. The cumulative MAE rates were 3% (3/89) at 6 months and 7% (6/89) at 1 year. Two patients underwent coil embolization of type II endoleaks at 6.5 months and 2.2 years, respectively. Clinical success was 94% (84/89) at 30 days, 98% (85/87) at 6 months, and 99% (82/83) at 1 year. **Conclusion:** Early results suggest that properly selected AAA patients can be safely treated using the Altura Endograft System with favorable midterm outcome. Thus, further clinical investigation is warranted to evaluate the role of this device in the treatment of AAA.

Keywords

abdominal aortic aneurysm, endograft, endoleak, endovascular aneurysm repair, mortality, reintervention, stent-graft

Introduction

Endovascular aneurysm repair (EVAR) has now largely replaced open surgery as the procedure of choice for patients with infrarenal abdominal aortic aneurysm (AAA). More than 75% of patients with unruptured AAAs in the United States, Germany, and some European countries are now treated with EVAR.^{1–5} A variety of commercially available endovascular devices provide excellent results for patients with suitable anatomy. Yet, there is room for improvement because type I endoleaks can occur due to neck dilatation or graft migration. In addition, many patients have anatomic constraints related to the aortic neck or iliac arteries that may compromise results. Usable

aortic neck length may be significantly affected by aortic angulation and the location of the renal arteries, which are often not at the same level. Nonetheless, many patients are treated with endografts outside the manufacturers' instructions for use (IFUs), often with suboptimal results⁴ that lead to ongoing concerns regarding long-term durability and occurrence of late ruptures.^{5,6}

Manufacturers have made significant advances in improving existing devices to compensate for short and angulated aortic necks. However, efforts have also been made to extend the proximal fixation zone in such patients to the suprarenal aorta by adding chimneys, snorkels, branches, and fenestrations to existing endografts.^{7,8} While early results of these techniques are promising,⁹ the

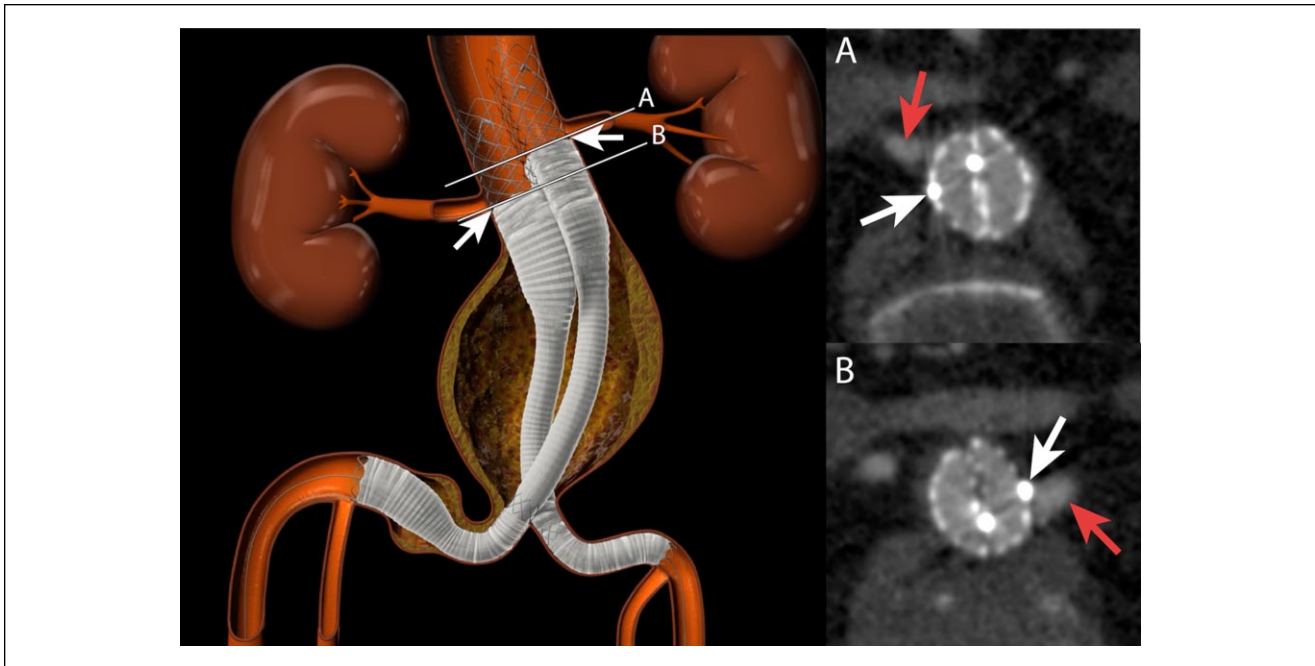


Figure 1. Schematic image of the Altura endograft with offset proximal D-shaped stents, which aid in optimizing aortic neck fixation in relation to the renal arteries and distal iliac fixation at the orifice of the internal iliac arteries. The white lines show the proximal edge of the (A) right and (B) left graft fabric material. Cross-sectional computed tomography images demonstrate the device fabric material markers (white arrows) just below the origin of the renal arteries (red arrows).

procedures are complex and costly, and long-term results are lacking.⁷

The Altura endoprosthesis (Lombard Medical, Ltd, Oxford, UK) is a new, low-profile endograft designed to simplify the treatment of infrarenal AAA and optimize both proximal and distal fixation in the setting of uneven and/or complex anatomy. Its unique design uses 2 proximal D-shaped self-expanding endografts with suprarenal fixation, each in a 14-F delivery system. No gate cannulation is required, and each limb of the device can be precisely positioned both proximally and distally to maximize available fixation length. The purpose of this report is to analyze the midterm clinical results of the Altura Endograft System based on 2 prospective clinical studies with follow-up extending from 1 to 4 years.

Methods

Device Description

The Altura Endograft System is composed of 2 proximal D-shaped endografts that are positioned back to back so that together they form a round circumference in the aortic neck for secure sealing (Figure 1). The stents are made from braided nitinol and covered with crimped woven polyester graft material that moves in concert with the braid as it is shortened or expanded to its preset diameter, resulting in a flexible, compliant, and kink-resistant endograft suitable for tortuous anatomy. The stent-grafts can be repositioned in relation to each renal artery as many times as needed prior to final deployment to fully use available neck length, which is particularly useful in cases of severe neck angulation

¹Department of Vascular Surgery, Pauls Stradins Clinical University Hospital, University of Latvia, Riga, Latvia

²Department of Vascular and Endovascular Surgery, Pontificia Universidad Católica de Chile, Santiago, Chile

³Department of Invasive Radiology, Pauls Stradins Clinical University Hospital, University of Latvia, Riga, Latvia

⁴Department of General and Vascular Surgery, Poznan University of Medical Sciences, Poznan, Poland

⁵Department for Vascular Medicine, Vascular Surgery, Angiology, and Endovascular Therapy, University Heart Center Hamburg, University Hospital Hamburg-Eppendorf, Hamburg, Germany

⁶Department of Vascular and Endovascular Surgery, University Hospital Düsseldorf, Germany

⁷Department of Surgery, Stanford University Medical Center, Stanford, CA, USA

Corresponding Author:

Dainis Krievins, Department of Vascular Surgery, Pauls Stradins Clinical University Hospital, University of Latvia, Pilsonu Street 13, Riga, LV-1002, Latvia.

Email: dainis.krievins@stradini.lv

Table 1. Baseline Characteristics of the 90 Patients in the Study.^a

Age, y	72.8±8.3 (57–99)
Men	79/90 (88)
History of CAD	37/89 (42)
History of heart surgery	13/90 (14)
Hyperlipidemia	33/77 (43)
Hypertension	54/86 (63)
Smoking	64/90 (71)
Family history of AAA	6/82 (7)
AAA diameter, ^b mm	53.8±5.7 (45.0–70.0)

Abbreviations: AAA, abdominal aortic aneurysm; CAD, coronary artery disease.

^aContinuous data are presented as the means ± standard deviation (range); categorical data are given as the counts/sample (percentage).

^bInvestigator reported.

and tortuosity. The Altura D-shaped endografts are available in diameters ranging from 24 to 30 mm.

The modular iliac component is unique in that it is deployed from distal to proximal for precise positioning at the internal iliac artery orifice, which maximizes distal fixation length as well as compensating for axisymmetric iliac alignment in tortuous iliac arteries. There is a generous overlap at the junction of the proximal aortic and iliac modules, which provides great flexibility in length adjustment during deployment. The delivery system permits contrast injection at the landing zones to facilitate precise placement without the need for supplementary catheters. The Altura iliac modules are available in diameters ranging from 13 to 21 mm.

Study Design and Patient Population

Two prospective clinical studies were conducted at 10 clinical sites in 4 countries (Latvia, Poland, Germany, and Chile) from 2011 to 2015: the Altura AAA Endograft Safety and Feasibility Study for Exclusion of Abdominal Aortic Aneurysms (44 patients) and the ELEVATE International: Kissing Endografts for Peripheral AAA Exclusion (46 patients). Key inclusion criteria for both studies included AAA diameter >50 mm or recent diameter increase >5 mm, neck diameter 18 to 28 mm, neck length ≥15 mm, neck angulation ≤60°, iliac diameter 8 to 18 mm, iliac fixation length ≥15 mm, and accessibility by a 14-F delivery system. Exclusion criteria included thoracic or suprarenal aneurysm; ruptured, leaking, or dissecting aneurysm; prior surgical or endovascular repair; or thrombus, calcification, or plaque in the neck that could compromise sealing. Each participating center's institutional review board approved the protocol, and all patients signed informed consent.

Because the indications for use, study objectives, eligibility criteria, procedural requirements, clinical and imaging-based follow-up, and primary and secondary endpoints were similar, the populations from each trial were combined

for this analysis. Baseline demographics for the 90 patients (mean age 72.8±8.3 years; 79 men) are shown in Table 1. Preoperative aneurysm diameter was 53.8±5.7 mm (range 45–70). The infrarenal aortic neck diameter was 22.3±7.7 mm (range 15–28), the neck length was 22.0±8.5 mm (range 14–35), and the neck angle was 38°±25° (range 3°–67°).

Data Collection, Follow-up, and Definitions

Preoperative, intraoperative, and follow-up data were collected according to prospectively defined protocol parameters and maintained in an audited central registry. Clinical follow-up with a ±2-week window was planned at discharge, 30 days, 6 months, 12 months, and yearly intervals thereafter up to 5 years with contrast-enhanced computed tomography (CT) scans performed at each time point after discharge. All pre- and postoperative CT scans were reviewed by 2 independent radiologists. Follow-up CT scan measurements included aneurysm diameter (largest minor axis sac diameter per the reporting standard¹⁰), cross-sectional area, and endograft position with respect to superior mesenteric artery and vertebral body reference points. The first postprocedure CT scan (within 30 days) was used as the baseline for comparison of quantitative morphological changes on follow-up CT scans.

Outcome measures included mortality, major adverse events [MAEs: all-cause death, stroke, paraplegia, myocardial infarction (MI), respiratory failure, bowel ischemia, and blood loss ≥1000 mL], and clinical success (freedom from procedure-related death, type I or III endoleak, thrombosis, migration, reintervention, or AAA rupture).¹⁰ Aneurysm enlargement/decrease was defined as ≥5-mm change, and migration was defined as ≥10-mm change. Clinical outcome events were reviewed by an independent Clinical Events Committee (CEC).

Statistical Analysis

The data are presented as the mean ± standard deviation or median with interquartile range (IQR: Q1, Q3) as appropriate. Statistical comparison of individual measures was performed using the paired *t* test or Fisher exact test; significance was assumed at *p*<0.05. Statistical analysis was performed with GraphPad Prism (version 6.0; GraphPad Software, San Diego, CA, USA).

Results

Early Outcomes

Altura endografts were successfully implanted in 89 (99%) of 90 study subjects. The single failure was due to delivery system malfunction prior to device insertion; the patient

Table 2. In-Hospital Outcomes.^a

Vessel access type	
Percutaneous	51 (57)
Surgical	39 (43)
Anesthesia type	
Regional/epidural/spinal	66 (73)
General	19 (21)
Local	5 (6)
Fluoroscopy time, min	26±12; 23 (9–80)
Contrast volume, mL	182±79; 170 (30–450)
Procedure time, min	117±46; 106 (50–300)
Blood loss, mL	267±227; 200 (1–950)
Length of stay, d	
Hospital	2.9±1.4 (2–9)
Intensive care unit	0.5±0.6 (0.0–3.0)
Mortality at 30 days	1 (1)

^aContinuous data are presented as the means ± standard deviation and median (range); categorical data are given as the counts/sample (percentage).

was successfully treated with a commercially available endograft and was subsequently withdrawn from the study per protocol. This event occurred in the initial generation (Gen) 1.0 device and prompted delivery system modification. Since then no similar events have been observed. In all, 25 patients were treated with the Gen 1.0 and 1.25 Altura Endograft Systems (no longer available), while the remaining 65 patients were treated with the Gen 2.0 Endograft System [Conformité Européenne (CE) mark 2015]. Improvements to the device delivery system were made in these iterations, with no significant changes to the endograft itself.

The majority (67, 74%) of patients were treated with the standard combination of 2 aortic endografts and 2 iliac endografts. Because of patient-specific anatomic variability, 23 (26%) were successfully treated with some variation during the index procedure, including 8 patients treated with 2 aortic endografts alone, 2 patients treated with 2 aortic endografts and 1 iliac endograft, and 9 treated with 2 aortic endografts and 3 or 4 iliac endografts. Four patients required an additional endograft bridging module for lengthy iliac arteries.

Procedure details are shown in Table 2. Choice of anesthesia and access were dictated by local site preferences. Percutaneous access was obtained in 51 (57%) subjects and surgical access in the remaining 39 (43%) subjects. The time required for inserting and deploying the Altura devices averaged 117±46 minutes (range 50–300), during which 182±38 mL of contrast were used.

All patients recovered from the implant procedure uneventfully; there were no groin complications. Subjects spent a mean 0.5±0.6 days in the intensive care unit (standard of practice for the participating sites). The mean length of the hospital stay was 2.9±1.4 days (range 2–9). There

was no in-hospital mortality, but 1 (1%) patient with a history of MI and 2 prior coronary revascularization procedures died unexpectedly 8 days after the procedure. No autopsy was performed, and the CEC review listed the cause of death as unknown. No additional MAEs were observed within the first 30 days.

In the first month, 4 (4%) of 89 patients underwent a reintervention: 1 patient had a type Ib iliac endoleak that was treated with an additional iliac stent-graft, 1 patient had iliac limb stenosis treated with an iliac stent, another iliac limb stenosis was treated with balloon angioplasty, and 1 patient had aortic endograft occlusion on postoperative day 21, which was successfully treated with a femorofemoral bypass. Thus, clinical success at 30 days was achieved in 84 (94%) of 89 patients. Of note, type II endoleaks were seen in 20 (23%) of 88 patients at 30 days.

Outcomes in Follow-up

No patients were lost to follow-up, and all patients treated with the Altura device had ≥12-month surveillance. Imaging follow-up was available in 87 patients at 6 months, 83 patients at 1 year, 31 patients at 2 years, 13 at 3 years, and 6 at 4 years. During a median follow-up of 12.5 months (IQR 11.7, 17.0; absolute range 11.5–50.9), there were no aneurysm ruptures, conversions to surgery, or aneurysm- or device-related deaths as adjudicated by an independent medical review. Four additional patients died at 4.5 months (pneumonia), 6 months (acute MI), 1.8 years (unknown cause; 1-year imaging revealed no endoleak and 4-mm AAA decrease), and 1.9 years (heart failure). In addition, 1 patient experienced an MI 11 months following the index procedure. The cumulative MAE rates were 3% (3/89) at 6 months and 7% (6/89) at 1 year. There was a late type Ia endoleak that was related to a calcium nodule in the infrarenal aortic neck. An endoleak had been seen in the same location immediately after device deployment and disappeared after balloon dilation; it was not seen at 30 days or 6 months but reappeared at 1 year. There was no change in aneurysm size, and the endoleak was no longer present at subsequent 2- and 3-year follow-up. No secondary procedure was performed, and aneurysm size at 3 years was decreased 5 mm compared to the 30-day dimensions.

Two patients underwent successful coil embolization of type II endoleak at 6.5 months and 2.2 years after the index procedure. There was no change in AAA size before or after the secondary procedure in either patient, and the endoleaks were not present on subsequent imaging. No additional patients underwent a secondary procedure. Freedom from reintervention (Figure 2) at 3 years was 88.9% (95% CI 60.1 to 97.3). Clinical success was 98% (85/87) at 6 months and 99% (82/83) at 1 year (Table 3). Mean AAA diameter decreased from 5.2±5.3 cm on the 30-day CTA to 4.6±5.9 cm at the latest scan; no patient had an increase in AAA

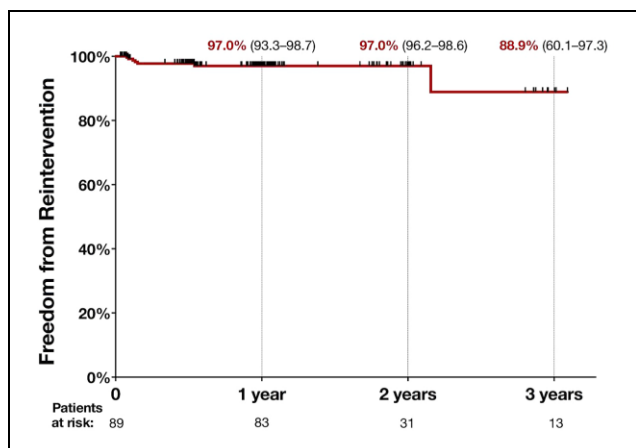


Figure 2. Kaplan-Meier curve showing freedom from reintervention following treatment using the Altura Endograft System.

diameter >5 mm. Eighteen (20%) patients had untreated type II endoleaks during the observation period.

CT Image Analysis

Independent review of the CT scans available at each time point demonstrated widely patent endograft lumens, with no evidence of thrombi or stent fractures. Aneurysm size was reduced or unchanged in all patients at 1 and 2 years, with no patient experiencing an increase in diameter ≥ 5 mm. The mean aneurysm size decreased by 6.0 mm at 1 year and 7.5 mm at 2 years. Endograft movement >10 mm was detected in 1 patient at 2 years. This patient, who received a Gen 1 device, had 14.8-mm distal movement of one iliac limb module and 7.8-mm movement of the other. Nonetheless, the aneurysm size decreased by 5.6 mm at 1 year and 11.7 mm at 2 years; there was no endoleak, and no additional movement occurred over the next 2 years.

Discussion

The Altura endograft provides a new and unique approach to the treatment of infrarenal aneurysms, with a number of potential advantages over existing devices, including a low-profile 14-F delivery system, simplified repositionable deployment, and the ability to individually and precisely position the endograft below each renal artery (Figure 1) and above each iliac bifurcation (Figure 3). These features permit the treatment of many patients who otherwise would be excluded as candidates for EVAR, including AAA patients with small distal aortas or concomitant occlusive disease.

The need for lower profile endograft delivery systems is well recognized, as significant access-related complications occur in 5% to 17% of cases.¹¹ Poor access is the most

common exclusion criterion for EVAR, particularly in women¹² and Asians.¹³ Difficult access through small-caliber, calcified, and diseased iliac arteries can lead to limb occlusion, limb stenosis, and kinking and is the leading cause of conversion to open repair.¹¹ Iliac tortuosity is related to patient outcome¹⁴ and has been implicated in type Ib endoleaks as well as limb occlusion.¹⁵

Devices using small-caliber delivery systems are now becoming available, with promising early results.¹⁶⁻¹⁸ Sweet et al¹² showed that 19% of men and 51% of women have bilateral iliac artery diameters <6 mm, and Kristmundsson et al¹⁹ estimated that lower-profile aortic endografts could increase the proportion of patients suitable for EVAR by up to 60%. The Altura endograft achieves a 14-F ultralow profile without compromising the stent wire gauge due to the braided nitinol stent. Fabric thickness is likewise unaffected as the crimped fabric elongates and narrows for loading into the small diameter delivery sheath. When deployed, the expanded endograft is flexible and resistant to radial compressive forces, resulting in a reduced risk of kinking.

Aneurysm neck anatomy is the single most important determinant of successful EVAR. Reports of anatomic suitability for EVAR vary from 25% to 69%,²⁰ and hostile neck anatomy is directly related to adverse outcomes, including type I endoleak, AAA-related death, rupture, and need for secondary procedures.²¹ The most common disqualifying feature in these studies is a short infrarenal neck, which is often exacerbated by neck angulation, a criterion that alone excludes 15% to 20% of patients from EVAR.²² The length of usable infrarenal neck can also be compromised by uneven origins of the renal arteries or renal artery offset due to severe aortoiliac tortuosity, resulting in angulation of the perirenal aortic segment relative to the axis of the guidewire. Since the endograft must be positioned below the lowermost renal artery, proximal fixation length may be compromised when using single-body bifurcated endografts. The parallel-endograft Altura system compensates for renal artery disparities by allowing longitudinal adjustment of each endograft module for optimal positioning just below the renal orifice. Each module can be expanded, collapsed, and repositioned as desired prior to release of the suprarenal fixation mechanism, thus allowing full utilization of available infrarenal neck to maximize fixation length.

Similarly, maximum iliac fixation can be achieved with the Altura device by precise positioning of each iliac limb in relation to the internal iliac artery using a unique distal to proximal iliac deployment system. The distal end of the iliac device is unsheathed first at the desired location and is maintained in that position during proximal device deployment. This is particularly useful when iliac seal zones are short and angulated. In addition to precise distal localization, the length of the iliac limb can be adjusted as needed to accommodate iliac tortuosity and angulation, which

Table 3. Clinical Outcomes Based on Evaluable Computed Tomography Angiography Images.^a

	30 Days (n=88) ^b	6 Months (n=87) ^c	1 Year (n=83) ^d	2 Years (n=31)	3 Years (n=13)	4 Years (n=6)
Clinical success (%)	94	98	99	94	100	100
AAA size, mm	52.1±5.3	48.4±7.4	46.1±5.9	45.2±9.6	45.8±12.4	44.5±13.5
Type I, III endoleaks	1	0	1	0	0	0
Endograft occlusion	1	0	0	0	0	0

Abbreviations: AAA, abdominal aortic aneurysm; n, number of evaluable computed tomography angiography images.

^aContinuous data are presented as the means ± standard deviation; categorical data are given as the counts (percentage).

^bOne of 89 patients was unavailable for imaging at this time point owing to death at 8 days.

^cOne patient was unavailable for imaging at this time point due to death at 136 days.

^dFour patients were unavailable for imaging at this time point, 3 due to death at 186, 223, and 265 days and 1 due to myocardial infarction and renal insufficiency.

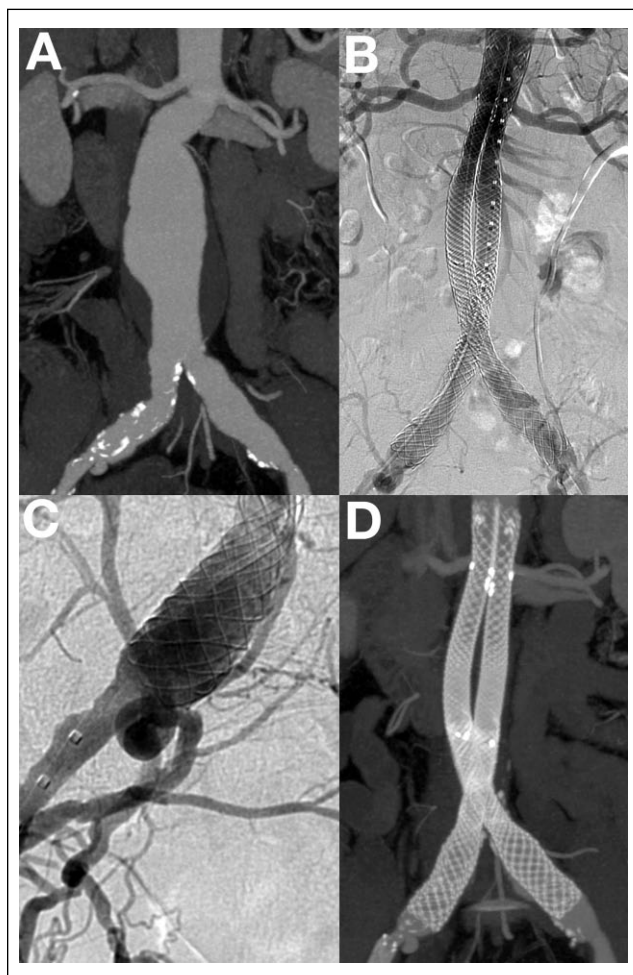


Figure 3. (A) Computed tomography angiography (CTA) of an abdominal aortic aneurysm with a 60° infrarenal angle, which was straightened immediately after placement of the Altura endograft (B). The 2 proximal D-shaped stents were positioned just below each renal artery to maximize use of the infrarenal neck. (C) Precise exclusion of the ectatic common iliac artery was achieved by deploying the iliac graft proximally from its distal position. (D) The 2-year CTA reconstruction demonstrated the stability of the device and a fully excluded aneurysm. At 3 years, the aneurysm size had decreased by 28 mm.

facilitates axisymmetric alignment of the iliac limb to the iliac outflow tract for optimum flow and endograft stability. The deleterious effects of tortuous iliac anatomy and suboptimal iliac fixation in relation to iliac limb complications, type Ib endoleaks, and endograft migration are well documented.^{14,15,23}

Finally, the bilateral parallel endograft platform significantly simplifies the EVAR procedure by eliminating the need for gate cannulation, and together with the advantages of the small caliber, the 14-F delivery system may prove to be useful when treating ruptured aneurysms. The Nellix Endovascular Aneurysm Sealing System (Endologix, Irvine, CA, USA) is similarly based on a parallel endograft system, with no need for gate cannulation. However, the Nellix device has a larger diameter delivery system and is held in place by polymer filled endobags that surround the stent and fill the aneurysm sac to potentially eliminate endoleaks. Early and midterm results with Nellix are promising,^{24,25} but the lack of positive fixation to the aortic neck may leave it vulnerable to late device migration.^{26,27} By contrast, the Altura endograft provides positive endograft fixation with a barbed suprarenal stent, which may provide improved long-term durability. Given the encouraging early results of this study in terms of low morbidity (2% at 6 months), type I endoleak (2% at 3 years), and reintervention (7% at 3 years), the Altura system compares favorably with results using currently available endovascular devices.^{28,29}

Limitations

The primary shortcomings of this study were the delivery system modifications that occurred during the course of the 2 studies and the combination of the populations for this analysis. About a quarter of all patients were treated with the Gen 1 device, which is no longer available. However, there were no significant changes in study protocol, endpoints, analytical methods, investigators, or endograft. In addition, data were available for all patients enrolled in both studies with ongoing image-based follow-up extending to 4 years.

Also, it should be noted that this study represents the initial clinical experience with a new endograft at multiple

sites with no prior experience with this device. This learning curve is reflected in the high contrast use because investigators documented each step of the procedure with multiple imaging studies in their initial cases. After this learning curve was passed and the Gen 2 device was approved, imaging requirements and contrast use diminished considerably. Because this was the first-in-human experience with this endograft, the results may not be generalizable or reflect outcomes that may be obtained with the currently available CE-marked device.

Conclusion

Results from the initial clinical studies of the Altura Endograft System are promising and suggest that properly selected patients with infrarenal AAA can be safely treated with favorable midterm clinical outcome. Further clinical investigation is warranted to evaluate the role of this device in the treatment of AAA.

Declaration of Conflicting Interests

The author(s) declared the following potential conflicts of interest with respect to the research, authorship, and/or publication of this article: Dainis Krievins and Alexander Oberhuber are consultants to Lombard Medical, Inc.

Funding

The author(s) disclosed receipt of the following financial support for the research, authorship, and/or publication of this article: Funding for this study was provided by Lombard Medical, Inc, Oxford, UK.

References

1. Dua A, Kuy SR, Lee CJ, et al. Epidemiology of aortic aneurysm repair in the United States from 2000 to 2010. *J Vasc Surg.* 2014;59:1512–1517.
2. Mani K, Verenermo M, Beiles B, et al. Regional differences in case mix and peri-operative outcome after elective abdominal aortic aneurysm in the Vascunet database. *Eur J Vasc Endovasc Surg.* 2015;49:646–652.
3. Trenner M, Haller B, Soelner H, et al. Twelve years of the quality assurance registry abdominal aortic aneurysm of the German Vascular Society (DGG). *Gefäßchirurgie.* 2013;18:206–213.
4. Schanzer A, Greenberg RK, Hevelone N, et al. Predictors of abdominal aortic aneurysm sac enlargement after endovascular repair. *Circulation.* 2011;123:2848–2855.
5. Patel R, Sweeting MJ, Powell JT, et al; EVAR trial investigators. Endovascular versus open repair of abdominal aortic aneurysm in 15-years' follow-up of the UK endovascular aneurysm repair trial 1 (EVAR trial 1): a randomised controlled trial. *Lancet.* 2016;388:2366–2374.
6. De Bruin JL, Baas AF, Buth J, et al.; DREAM Study Group. Long-term outcome of open or endovascular repair of abdominal aortic aneurysm. *N Engl J Med.* 2010;362:1881–1889.
7. Lee JT, Lee GK, Chandra V, et al. Early experience and lessons learned with fenestrated endografts compared with the snorkel/chimney technique. *J Vasc Surg.* 2014;60:849–856.
8. Katsargyris A, Oikonomou K, Klonaris C, et al. Comparison of outcomes with open, fenestrated, and chimney graft repair of juxtarenal aneurysms: are we ready for a paradigm shift? *J Endovasc Ther.* 2013;20:159–169.
9. Donas KP, Lee JT, Lachat M, et al. Collected world experience about the performance of the snorkel/chimney endovascular technique in the treatment of complex aortic pathologies: the PERICLES registry. *Ann Surg.* 2015;262:546–553.
10. Chaikof EL, Blankensteijn JD, Harris PL, et al.; Ad Hoc Committee for Standardized Reporting Practices in Vascular Surgery of The Society for Vascular Surgery/American Association for Vascular Surgery. Reporting standards for endovascular aortic aneurysm repair. *J Vasc Surg.* 2002;35:1048–1060.
11. Murray D, Ghosh J, Khwaja N, et al. Access for endovascular aneurysm repair. *J Endovasc Ther.* 2006;13:754–761.
12. Sweet MP, Fillinger MF, Morrison TM, et al. The influence of gender and aortic aneurysm size on eligibility for endovascular abdominal aortic aneurysm repair. *J Vasc Surg.* 2011;54:931–937.
13. Cheng SW, Ting AC, Ho P, et al. Aortic aneurysm morphology in Asians: features affecting stent-graft application and design. *J Endovasc Ther.* 2004;11:605–612.
14. Chaikof EL, Fillinger MF, Matsumura JS, et al. Identifying and grading factors that modify the outcome of endovascular aortic aneurysm repair. *J Vasc Surg.* 2002;35:1061–1066.
15. Coulston J, Baigent A, Selvachandran H, et al. The impact of endovascular aneurysm repair on aortoiliac tortuosity and its use as a predictor of iliac limb complications. *J Vasc Surg.* 2014;60:585–589.
16. Coppi G, Njila M, Coppi G, et al. INCRAFT® Stent-Graft System: one-year outcome of the INNOVATION Trial. *J Cardiovasc Surg (Torino).* 2014;55:51–59.
17. Torsello G, Scheinert D, Brunkwall JS, et al. Safety and effectiveness of the INCRAFT AAA Stent Graft for endovascular repair of abdominal aortic aneurysms. *J Vasc Surg.* 2015;61:1–8.
18. Mehta M, Valdés FE, Nolte T, et al. One-year outcomes from an international study of the Ovation Abdominal Stent Graft System for endovascular aneurysm repair. *J Vasc Surg.* 2014;59:65–73.e1-3.
19. Kristmundsson T, Sonesson B, Dias N, et al. Anatomic suitability for endovascular repair of abdominal aortic aneurysms and possible benefits of low profile delivery systems. *Vascular.* 2014;22:112–115.
20. Elkouri S, Martelli E, Głowiczki P, et al. Most patients with abdominal aortic aneurysm are not suitable for endovascular repair using currently approved bifurcated stent-grafts. *Vasc Endovascular Surg.* 2004;38:401–412.
21. Antoniou GA, Georgiadis GS, Antoniou SA, et al. A meta-analysis of outcomes of endovascular abdominal aortic aneurysm repair in patients with hostile and friendly neck anatomy. *J Vasc Surg.* 2013;57:527–538.
22. Hobo R, Kievit J, Leurs LJ, et al. Influence of severe infrarenal aortic neck angulation on complications at the proximal neck following endovascular AAA repair: a EUROSTAR study. *J Endovasc Ther.* 2007;14:1–11.

23. Benharash P, Lee JT, Abilez OJ, et al. Iliac fixation inhibits migration of both suprarenal and infrarenal aortic endografts. *J Vasc Surg.* 2007;45:250–257.
24. Donayre CE, Zarins CK, Krievins DK, et al. Initial clinical experience with a sac-anchoring endoprosthesis for aortic aneurysm repair. *J Vasc Surg.* 2011;53:574–582.
25. Thompson MM, Heyligers JM, Hayes PD, et al, for the EVAS FORWARD Global Registry Investigators. Endovascular aneurysm sealing: early and midterm results from the EVAS FORWARD Global Registry. *J Endovasc Ther.* 2016;23:685–692.
26. Carpenter JP, Cuff R, Buckley C, et al; Nellix Investigators. One-year pivotal trial outcomes of the Nellix system for endovascular aneurysm sealing. *J Vasc Surg.* 2017;65:330–336.e4.
27. England A, Torella F, Fisher RK, et al. Migration of the Nellix endoprosthesis. *J Vasc Surg.* 2016;64:306–312.
28. Wales L, Dunckley M, Bohm N, et al. Device-specific outcomes following endovascular aortic aneurysm repair. *Eur J Vasc Endovasc Surg.* 2008;36:661–667.
29. Verzini F, Isernia G, De Rango P, et al. Abdominal aortic endografting beyond the trials: a 15-year single-center experience comparing newer to older generation stent-grafts. *J Endovasc Ther.* 2014;21:439–447.