

One-year outcomes from an international study of the Ovation Abdominal Stent Graft System for endovascular aneurysm repair

Manish Mehta, MD, MPH,^a Francisco E. Valdés, MD,^b Thomas Nolte, MD,^c Gregory J. Mishkel, MD,^d William D. Jordan, MD,^e Bruce Gray, DO,^f Mark Eskandari, MD,^g and Charles Botti, MD,^h on behalf of “A Pivotal Clinical Study to Evaluate the Safety and Effectiveness of the Ovation Abdominal Stent Graft System” Investigators, Albany, NY; Santiago, Chile; Bad Bevensen, Germany; Springfield, Ill; Birmingham, Ala; Greenville, SC; Chicago, Ill; and Columbus, Ohio

Objective: This study evaluated 1-year safety and effectiveness outcomes of the United States regulatory trial for the Ovation Abdominal Stent Graft System (TriVascular Inc, Santa Rosa, Calif) for endovascular repair of abdominal aortic aneurysms (AAAs).

Methods: This prospective, multicenter, single-arm trial was conducted at 36 sites in the United States, Germany, and Chile to evaluate the safety and effectiveness of the Ovation stent graft. From November 2009 to May 2011, 161 patients (88% males; mean age, 73 ± 8 years) with AAAs (mean diameter, 54 ± 9 mm) were treated with the Ovation stent graft. The main body is a modular two-docking limb device with a 14F outer diameter delivery system, active suprarenal fixation, and polymer-filled proximal rings that accommodate the aortic neck for seal. Main inclusion criteria included proximal aortic neck length ≥7 mm, inner neck diameter between 16 and 30 mm, distal iliac landing zones length ≥10 mm, and diameter between 8 and 20 mm. Patients were treated under a common protocol, including clinical and imaging follow-up at discharge, 30 days, 6 months, and annually through 5 years. A Clinical Events Committee adjudicated adverse events, an independent imaging core laboratory analyzed imaging, and a Data Safety and Monitoring Board provided study oversight. Complete 1-year follow-up data were available for this report.

Results: The Ovation stent graft was implanted successfully in 161 patients (100%), including 69 (42.9%) by percutaneous access. General anesthesia was used in 106 patients (65.8%). Technical success was 100%, and mean procedure time was 110 minutes. Median procedural blood loss was 150 mL, and median hospital stay was 1 day. The 30-day major adverse event rate was 2.5%. At 1 year, AAA-related and all-cause mortality were 0.6% and 2.5%, respectively. Major adverse event and serious adverse event rates through 1 year were 6.2% and 38.5%, respectively. The 1-year treatment success rate was 99.3%. The imaging core laboratory reported no stent graft migration or type I, III, or IV endoleaks. At 1 year, type II endoleaks were identified in 34% of patients, and AAA enlargement was identified in one patient (0.7%). No AAA rupture or conversion to open surgery was reported. AAA-related secondary procedures were performed in 10 patients (6.2%) for 12 findings, including endoleak (six), aortic main body stenosis (three), and iliac limb stenosis or occlusion (three).

Conclusions: The 1-year results of the Ovation Abdominal Stent Graft System demonstrate excellent safety and effectiveness in treatment of patients with AAAs, particularly in patients with challenging anatomic characteristics, including short aortic necks and narrow iliac arteries. Longer-term follow-up is needed. (J Vasc Surg 2013;■:1-9.)

Endovascular aneurysm repair (EVAR) reduces rupture risk and results in lower postoperative mortality and morbidity rates as well as a shorter convalescence compared with open surgical repair.¹⁻³ Consequently, EVAR has become the treatment of choice at many centers for patients with an abdominal aortic aneurysm (AAA) and

has outnumbered open surgical repair 2.5 to 1.⁴ Despite the well-established clinical benefits of EVAR and the availability of six United States (U.S.) Food and Drug Administration-approved devices in the U.S., the utility of endovascular technology remains limited.⁵⁻¹⁰ Even today, up to 50% of patients who are considered for

From the Vascular Group, PLLC, Albany^a; the Pontificia Universidad Católica de Chile, Santiago^b; the Herz- und Gefäßzentrum, Bad Bevensen^c; the Prairie Education and Research Cooperative, Springfield^d; the University of Alabama-Birmingham, Birmingham^e; the Greenville Hospital System, Greenville^f; the Northwestern Memorial Hospital, Chicago^g; and the Riverside Methodist Hospital, Columbus.^h

TriVascular Inc provided funding for this study.

Author conflict of interest: Dr Mehta is on the advisory board of Cordis Corp. Dr Mehta is a speaker/consultant for Cordis Corp, TriVascular Inc, ev3 Endovascular Inc, W. L. Gore and Associates Inc, Medtronic Inc, CardioMEMS Inc, Aptus Endosystems Inc, and Abbot Vascular Inc. Dr Mehta receives research grants from Aptus Endosystem Inc, Bolton Medical Inc, CardioMEMS, Cordis Corp, ev3 Endovascular, Harvest Technologies Corp, LeMaitre Vascular Inc, Lombard Medical

Technologies, MAQUET Cardiovascular LLC, Medtronic Vascular Inc, Terumo Cardiovascular Systems Corp, TriVascular Inc, and W. L. Gore and Associates Inc. Dr Mehta, Dr Nolte, and Dr Valdez received honorariums from TriVascular.

Additional material for this article may be found online at www.jvascsurg.org. Reprint requests: Manish Mehta, MD, MPH, The Vascular Group, PLLC, 43 New Scotland Ave, MC 157, Physicians Pavilion, 3rd Flr, Albany, NY 12208 (e-mail: mehtam@albanyvascular.com).

The editors and reviewers of this article have no relevant financial relationships to disclose per the JVS policy that requires reviewers to decline review of any manuscript for which they may have a conflict of interest.

0741-5214/\$36.00

Copyright © 2013 by the Society for Vascular Surgery.

<http://dx.doi.org/10.1016/j.jvs.2013.06.065>

EVAR are ultimately denied treatment due to challenging aortoiliac anatomy such as short and complex proximal aortic neck seal zones and narrow access vessels.¹¹⁻¹⁷ Furthermore, late complications after EVAR, including stent graft migration and loss of seal at the proximal aortic neck, remain a concern, particularly those that mandate secondary interventions or conversion to open repair. Hence, there remains a clinical need for continued advances in stent graft technology that can accommodate a wider range of aortoiliac morphology and offer a durable solution to AAA exclusion.

The Ovation Abdominal Stent Graft System (TriVascular Inc, Santa Rosa, Calif) is a new device that is designed to overcome the limitations of currently available stent grafts and can accommodate a broad range of aortoiliac characteristics, navigate through complex iliac and femoral access, and provide a seal in complex proximal infrarenal aortic neck morphology. The purpose of this prospective, international, multicenter clinical study was to evaluate the safety and effectiveness of the Ovation stent graft for treatment of AAA.

METHODS

Ethics. All research procedures performed in this study were in strict accordance with a common, predefined protocol that was prospectively registered at ClinicalTrials.gov as NCT01092117 (U.S.), NCT01097772 (Germany), and NCT01082185 (Chile). The investigational protocol and informed consent form were approved by an Institutional Review Board or Ethics Committee, and all study participants gave written informed consent before study participation.

Patients. This prospective, single-arm, multicenter trial enrolled 161 patients from 36 sites in the U.S., Germany, and Chile ([Supplementary Table I](#), online only). Patients underwent elective treatment with the Ovation stent graft between November 2009 and May 2011. Eligible patients presented with an AAA requiring intervention, were candidates for open surgery, and had aortoiliac characteristics suitable for treatment with the Ovation stent graft. The primary entry criteria included:

- A proximal neck length of ≥ 7 mm and an inner diameter of between 16 and 30 mm;
- A juxtarenal aortic neck angulation of $\leq 60^\circ$ if the proximal neck length was ≥ 10 mm or $\leq 45^\circ$ if the proximal neck length was < 10 mm;
- A distal seal zone of ≥ 10 mm and diameter between 8 and 20 mm; and
- An AAA diameter of ≥ 5.0 cm, 1.5 times the adjacent nonaneurysmal aorta, or expansion of ≥ 0.5 cm in the previous 6 months.

Complete inclusion and exclusion criteria are presented in [Supplementary Table II](#) (online only).

Preprocedural evaluation. Participants were consecutively evaluated for study eligibility. Patients who met all study entry criteria were evaluated for demographic

information and medical history and underwent a physical examination, laboratory testing, and contrast-enhanced spiral abdominal/pelvic computed tomography (CT) imaging.

Device description. The Ovation stent graft was designed to overcome the limitations of previous stent grafts by accommodating a broader range of aortoiliac anatomy with a low-profile 14F outer diameter (OD) delivery system and a proximal aortic neck seal mechanism designed to conform to and accommodate the aortic neck. The Ovation stent graft is characterized by a trimodular design, with the aortic body delivered by a flexible hydrophilic-coated 14F OD catheter, the smallest profile of any currently commercially available stent graft ([Fig 1](#)). The aortic body consists of a low-permeability polytetrafluoroethylene (PTFE) graft and a suprarenal nitinol stent with integral anchors to achieve active fixation to the aortic wall.

The aortic body contains a network of inflatable channels and sealing rings that are filled during deployment with a low-viscosity, radiopaque fill polymer that cures in situ to create a conformable seal to the patient's aortic neck. The Ovation iliac limbs consist of highly flexible nitinol stents encapsulated in low-permeability PTFE that are packaged in low-profile 13F to 14F OD delivery systems. Examples of typical pre-to-post radiographic findings with the Ovation stent graft are provided in [Figs 2 and 3](#).

Procedure. The EVAR procedure steps include femoral artery cutdown or percutaneous approach. Both techniques were left up to the discretion of the operator. Subsequent to bilateral femoral access, the trimodular stent graft is delivered and deployed from the ipsilateral side in three stages, which include unsheathing the main body, deploying the suprarenal bare-metal stent, and engaging the polymer, which is prepared on the back table and engaged through an automated plunger and exerts 1 atmosphere of pressure to be delivered into and expand the stent graft main body rings that subsequently conform to the aortic neck. The iliac rings along the main body provide support for the ipsilateral and contralateral iliac extensions.

Follow-up schedule. Patients were monitored through hospital discharge and returned for follow-up visits at 1 month, 6 months, and annually thereafter through 5 years. At each visit, patients underwent a physical examination, laboratory testing, contrast-enhanced spiral abdominal/pelvic CT (not performed at discharge), and four-view X ray imaging.

Outcomes. Safety outcomes included Clinical Events Committee (CEC) adjudicated major adverse events (MAEs), serious adverse events (SAEs), and mortality (all-cause and AAA-related). The primary safety end point was the incidence of MAEs through 30 days, defined as death, myocardial infarction, stroke, renal failure, respiratory failure, paraplegia, bowel ischemia, or procedural blood loss ≥ 1000 mL. AAA-related mortality was defined as death due to AAA rupture, due to any procedure

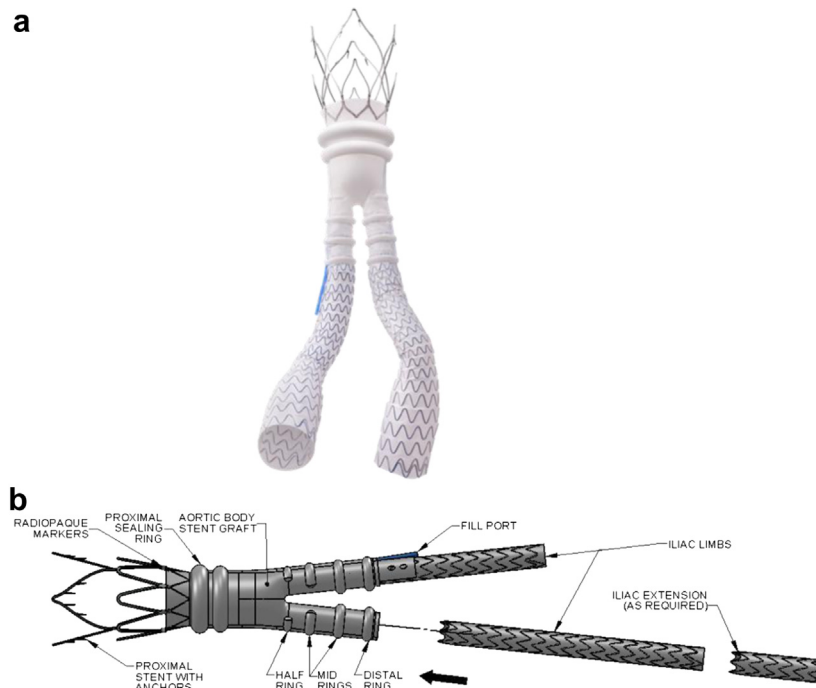


Fig 1. The Ovation Abdominal Stent Graft System: (a) image of deployed device and (b) schematic of deployed device with key design characteristics labeled.

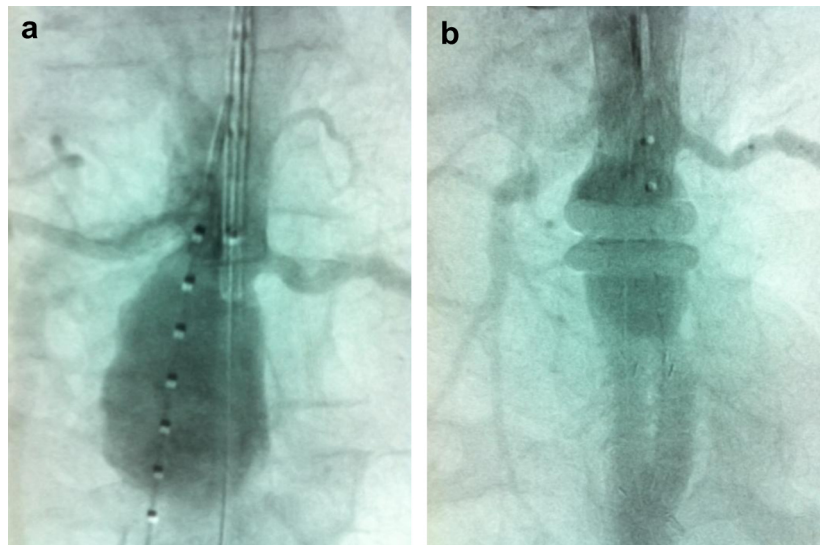


Fig 2. a, Preoperative angiogram shows the aneurysm and (b) a postoperative angiogram demonstrates successful aneurysm exclusion with the Ovation Abdominal Stent Graft System.

intended to treat the AAA, ≤ 30 days of any procedure intended to treat the AAA, or any in-hospital death if hospitalization was >30 days. An SAE was defined as any event that was fatal, life-threatening, required prolonged hospitalization (>48 hours), was a persistent or significant disability or incapacity, or was considered an important medical event.

Measures of device effectiveness included technical success (successful delivery and deployment of the aortic body and both iliac limbs), imaging core laboratory assessments of endoleak, stent graft migration, AAA enlargement, and stent fracture, as well as site-reported assessments of aortic main body stenosis, AAA rupture, AAA-related secondary intervention, and conversion to open surgery.

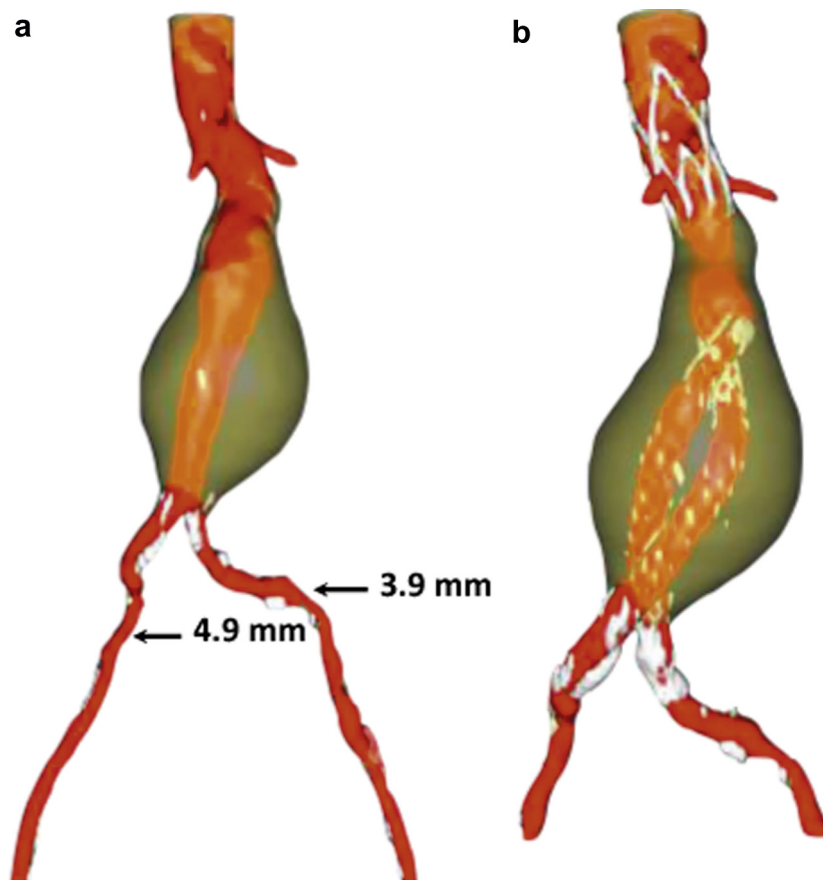


Fig 3. A computed tomography (CT) reconstruction shows the aneurysm (a) preoperatively and (b) demonstrates at 1 year successful aneurysm exclusion with the Ovation Abdominal Stent Graft System in a patient with challenging anatomy. Aortoiliac characteristics include proximal neck length of 7 mm with thrombus, juxtarenal angulation of 49°, and access vessel diameter of 3.9 mm (*left*) and 4.9 mm (*right*).

The primary effectiveness end point was the proportion of patients who experienced treatment success at 1 year, which was defined as technical success and freedom from all of the following: type I and III endoleak at 1 year, stent graft migration (defined as evidence of proximal or distal movement of the stent graft >10 mm relative to fixed anatomic landmarks compared with the 1-month CT scan) at 1 year, and AAA enlargement at 1 year (defined as a >5-mm AAA diameter increase compared with the AAA diameter on the 1-month CT scan), all as confirmed by the core imaging laboratory; AAA rupture through 1 year; and conversion to open surgery through 1 year.

Data quality. All research procedures followed a common protocol, and each site received thorough and consistent device and protocol training. All data were recorded on case report forms using an electronic data capture system (Phase Forward Inc, Waltham, Mass) and monitored for accuracy by TriVascular Inc. An independent imaging core laboratory (M2S Inc, West Lebanon, NH) analyzed all preoperative and postoperative CT scans and radiographs. A CEC reviewed and adjudicated all device-related adverse events and SAEs and classified

MAEs. Adverse events were categorized using the Medical Dictionary for Regulatory Activities. An independent Data and Safety Monitoring Board (Axio Research Acquisition Co, LLC, Seattle, Wash) regularly monitored the progress of the trial.

Hypotheses. The primary safety hypothesis was tested by comparing the 30-day incidence of MAEs in patients treated with the Ovation stent graft to a predefined target performance goal of 21%. The primary effectiveness hypothesis was tested by comparing the 1-year composite treatment success rate in patients treated with the Ovation stent graft to a predefined target performance goal of 80%.

Statistical analysis. Statistical tests for main study outcomes were prespecified in a statistical analysis plan. Continuous variables are reported as mean \pm standard deviation or median, depending on normality assumptions. Categorical variables are presented as number (%). The safety and effectiveness hypotheses were each tested by calculating a one-sided 95% confidence limit using the Wilson method¹⁸ and then comparing with the target performance goal. All safety outcomes that identified ≤ 365 days of endovascular AAA treatment were included in the analysis.

Table I. Baseline patient characteristics

Characteristic	Values ^a
Age, years	73 ± 8
Male gender	88 (141/161)
ASA classification	
I	6 (9/161)
II	28 (45/161)
III	60 (96/161)
IV	7 (11/161)
Medical history ^b	
Hypertension	85 (136/161)
Hyperlipidemia	70 (113/161)
Smoking	70 (113/161)
Coronary artery disease	45 (72/161)
Chronic obstructive pulmonary disease	27 (44/161)
Peripheral vascular disease	24 (38/161)
Arrhythmia	22 (35/161)
Diabetes mellitus	21 (34/161)
Myocardial infarction	21 (33/161)
Renal failure/insufficiency	14 (22/161)
Carotid artery disease	13 (21/161)
Valvular heart disease	12 (19/161)
Aortoiliac morphology	
Proximal neck length, mm	23 ± 13
Juxtarenal angle, °	19 ± 14
Maximum aneurysm diameter, mm	54 ± 9
Left common iliac diameter, mm	13.7 ± 3.3
Left minimum iliac access diameter, mm	7.0 ± 1.6
Right common iliac diameter, mm	13.9 ± 3.0
Right minimum iliac access diameter, mm	7.0 ± 1.6

ASA, American Society of Anesthesiologists.

^aValues are presented as percentage (n/N) or mean ± standard deviation.

^bConditions listed with frequency ≥10%.

All imaging data attained through the 1-year follow-up visit, which conservatively included images taken through 18 months to account for late follow-up visits, were analyzed and included in this report. Patients with readable imaging during each respective follow-up interval were included in the denominator for relevant effectiveness end points. Data were analyzed by an independent statistician using SAS 9.2 software (SAS Institute Inc, Cary, NC). Details regarding the patient inclusion and exclusion criteria, procedure details, and all investigators and sites are presented in the [Supplementary materials](#) (available online).

RESULTS

Patient accountability. A total of 92 screened patients were deemed ineligible for participation in the study based on inclusion or exclusion criteria. The most common causes of screening failures were presence of significant aortic neck angulation, aortic neck length of <7 mm, and aortic neck diameter of <16 mm or >30 mm. A total of 161 patients who met eligibility criteria were enrolled and underwent EVAR with the Ovation stent graft. Enrollment included 111 patients from 28 sites in the U.S., 30 patients from seven sites in Germany, and 20 patients from one site in Chile. Through 1 year, four patients died, four patients withdrew, and one patient was lost to

Table II. Procedural details

Characteristic	Values ^a
Access	
Delivery success	100 (161/161)
Vascular access	
Cutdown	52 (84/161)
Percutaneous	43 (69/161)
Percutaneous and cutdown	5 (8/161)
Procedure	
Deployment success	100 (161/161)
Anesthesia type ^b	
General	66 (106/161)
Local	24 (38/161)
Regional	17 (27/161)
Conscious sedation	11 (18/161)
Procedure time, minutes	110 ± 41
Procedural blood loss, mL ^c	150
Hospital length of stay, days ^c	1
Devices	
Aortic body diameter	
20 mm	3 (4/161)
23 mm	22 (35/161)
26 mm	36 (58/161)
29 mm	28 (45/161)
34 mm	12 (19/161)
Iliac limb diameter	
10 mm	6 (20/366)
12 mm	22 (80/366)
14 mm	35 (128/366)
16 mm	17 (62/366)
18 mm	14 (52/366)
22 mm	7 (24/366)

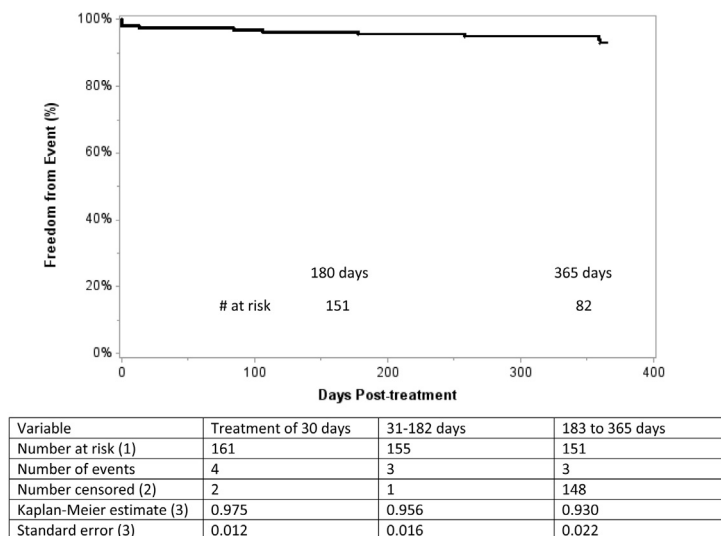
^aValues are presented as percentage (n/N) or mean ± standard deviation, unless otherwise noted.

^bNumerator >161 due to multiple methods used in some patients.

^cMedian.

follow-up. Complete 1-year follow-up data were available for all other patients.

Baseline characteristics. Baseline patient characteristics are presented in [Table I](#). Of the 161 study participants, 141 (88%) were men, mean age was 73 years (range, 54-95 years), and mean maximal AAA diameter was 5.4 cm. Comorbidities included hypertension (85%), hyperlipidemia (70%), smoking (70%), coronary artery disease (45%), chronic obstructive pulmonary disease (27%), peripheral vascular disease (24%), diabetes mellitus (21%), and chronic renal insufficiency (14%). During this study, aortoiliac morphology was present in 39% of patients that fell outside of the indications for use of any currently FDA-approved stent grafts available in the U.S., including 25 patients with proximal aortic neck length <10 mm and 50 patients with minimum access vessel diameter of <6 mm. Twelve patients presented with both proximal aortic neck length of <10 mm and minimum access vessel diameter of <6 mm. The inclusion criteria included patients with maximum AAA diameter that was >1.5 times the transverse dimensions of an adjacent nonaneurysmal aorta; three patients in the study met this criterion and had maximum AAA diameters of between 3.8 and 4.0 cm.



1. Number of subjects at risk at beginning of interval
2. Subjects are censored because their last follow-up has not reached the end of the time interval, Or because they are lost to follow-up. In addition, all subjects followed beyond 365 days are censored At 365 days
3. Estimate made at the end of time interval

Fig 4. Kaplan-Meier curve shows freedom from major adverse events (MAEs) through 1 year.

Procedural data. Successful arterial access and device deployment was achieved in all patients (Table II). Totally percutaneous access was used in 69 patients (43%). The mean procedural-related blood loss was 150 mL, and the median hospitalization was 1 day.

Safety outcomes. The 30-day MAE rate, the primary safety end point of the study, was 3%, with an upper-bound 95% confidence interval of 5%. The 30-day MAE rate was significantly lower than the 21% target performance goal. The MAE rate through 1 year was 6% (Fig 4). There were no device-related MAEs based on CEC-adjudicated data through 1 year. AAA-related mortality through 1 year was 1%. All-cause mortality through 1 year was 3%. Causes of death included disseminated intravascular coagulation and abdominal sepsis (day 17), respiratory failure (day 95), multiple organ failure (day 178), and suspected thoracoabdominal aneurysm rupture (day 359; Table III).

The one 30-day death occurred in a 76-year-old patient in whom an unanticipated adverse device effect occurred, which was reported to the FDA. During the procedure, the fill tube that injects the fill material into the aortic body stent graft had become disconnected, and the fill material was injected intravascularly. The patient showed signs of anaphylactoid response during the procedure and was treated and stabilized before the EVAR procedure was completed, with adequate aneurysm exclusion. The patient was subsequently transferred to the intensive care unit and treated for multisystem organ failure. On postoperative day 16, patient returned to the operating room and underwent subtotal colectomy for a perforated bowel. The following day, patient died of multisystem organ failure and disseminated intravascular coagulopathy.

A thorough root cause analysis was launched, and the evaluation identified a defective molded polycarbonate component (distal stop) that allowed the port for the fill material to prematurely disconnect from the aortic stent graft main body catheter. The distal stop provides a component “lock” to maintain connection of the fill port to the fill tube during fill material injection. Investigation of the delivery catheter confirmed that this component was fractured, which could have led to less force required to inadvertently disconnect the fill tube. TriVascular worked with the FDA in taking appropriate steps to modify the distal stop, which then was tested by simulated use to verify the modifications met the specifications and requirements. Furthermore, protocol, informed consent, and instructions for use modifications were implemented, including the exclusion criteria of a known allergy to polyethylene glycol-based polymers, before the trial was continued.

Effectiveness outcomes. The 1-year treatment success rate, the primary effectiveness end point of the study, was 99% with a lower-bound 95% confidence interval of 97%. All patients were followed up for a minimum of 1 year. The 1-year treatment success rate was significantly higher than the 80% target performance goal. The imaging core laboratory reported no type I, III, or IV endoleaks or stent graft migration. AAA enlargement was identified by the imaging core laboratory in one patient (1%) at the 1-year follow-up (Table IV), but the site reported no AAA enlargement. Type II endoleak was identified in 49 patients (34%) at 1 year. Site-reported type I endoleaks were identified in three patients (2%), but the core laboratory did not identify any of these endoleaks as type I. Stent fractures were identified in four patients (3%) at 1 year, none of which

Table III. Safety outcomes through 1 year

Outcome	30 days % (n/N)	1 year % (n/N)
Death	0.6 (1/161)	3 (4/161)
SAEs ^a	13 (21/161)	39 (62/161)
Injury, poisoning, and procedural complications	4 (6/161)	9 (15/161)
Respiratory, thoracic, and mediastinal disorders	3 (5/161)	8 (13/161)
Vascular disorders	3 (4/161)	7 (11/161)
Cardiac disorders	2 (3/161)	7 (11/161)
Gastrointestinal disorders	2 (3/161)	7 (11/161)
Neoplasms	0%	6 (10/161)
General disorders and administration site conditions	4 (6/161)	6 (9/161)
Infections and infestations	0.6 (1/161)	5 (8/161)
MAEs	2.5 (4/161)	6 (10/161)
Myocardial infarction	1 (2/161)	3 (4/161)
Procedural blood loss ≥1000 mL	1 (2/161)	1 (2/161)
Renal failure	1 (2/161)	1 (2/161)
Bowel ischemia	0.6 (1/161)	1 (2/161)
Death	0.6 (1/161)	3 (4/161)
Respiratory failure	0.6 (1/161)	1 (2/161)
Stroke	0	0
Paraplegia	0	0

MAEs, Major adverse events; SAEs, serious adverse events.

^aSAEs were categorized by System Organ Class using the Medical Dictionary for Regulatory Activities.

resulted in an identifiable clinical sequelae or have required treatment. No AAA ruptures or conversion to open surgical repair have occurred. AAA-related secondary procedures were performed in 10 patients (6%) for 12 findings, including type I endoleaks (three), type II endoleaks (three), aortic main body stenosis (three), and iliac limb stenosis or occlusion (three). One patient underwent a secondary procedure to resolve two findings (type Ia endoleak and aortic main body stenosis). In a second patient, two secondary procedures were performed, one to resolve a type Ia endoleak and another to resolve a type Ib endoleak (Table V).

Post hoc analyses. Post hoc exploratory analyses of the primary study end points and AAA-related secondary procedures were conducted based on the presence or absence of challenging aortoiliac anatomy and based on access method. Challenging aortoiliac anatomy was defined as at least one access vessel of <6 mm in diameter or proximal neck length of <10 mm, or both, based on the imaging core laboratory measurement. Overall, 63 of 161 patients (39%) met these criteria. Of these, 39 (24%) had maximum iliac diameter of <6 mm only, 13 (8%) had an aortic neck length of <10 mm, and 11 (7%) had an iliac diameter of <6 mm and an aortic neck length of <10 mm. Of the 50 patients with iliac diameter <6 mm, 14 (28%) were women.

MAE rates through 30 days were comparable ($P = .16$) in patients with challenging anatomy (0% [zero of 63]) compared with those with typical anatomy (4% [four of 98]). All patients with challenging anatomy achieved

Table IV. Effectiveness outcomes through 1 year

Outcome	30 days % (n/N)	1 year % (n/N)
Radiographic events ^a		
Endoleak	44 (68/153)	39 (55/143)
Type I	0 (0/153)	0 (0/143)
Type II	41 (62/153)	34 (49/143)
Type III	0 (0/153)	0 (0/143)
Type IV	0 (0/153)	0 (0/143)
Indeterminate origin	4 (6/153)	4 (6/143)
Stent graft migration ^b	NA	0 (0/150)
AAA diameter change ^b		
≥5 mm increase	NA	0.7 (1/150)
<5 mm change	NA	67 (101/150)
≥5 mm decrease	NA	32 (48/150)
Stent fracture	0.6 (1/157)	3 (4/146)
Clinical events ^c		
Access failure	0 (0/161)	NA
Deployment failure	0 (0/161)	NA
AAA rupture	0 (0/161)	0 (0/161)
Conversion to open surgery	0 (0/161)	0 (0/161)
AAA-related secondary intervention	1 (2/161)	6 (10/161)

AAA, Abdominal aortic aneurysm; NA, not applicable.

^aPatients with readable imaging assessed by the core laboratory were included in the denominator for each respective outcome.

^bCompared with 1-month baseline image.

^cSite reported through 1 year.

treatment success. AAA-related secondary procedures were comparable and performed in 3% (two of 63) of patients with challenging anatomy compared with 8% (eight of 98) of those with typical anatomy ($P = .32$). Access was achieved by cutdown in 92 patients (57%) and was totally percutaneous in 69 (43%). Overall, clinical outcomes in these subgroups were comparable, including MAE (5.4% vs 7.2%) and treatment success (99% vs 100%), for cutdown and percutaneous access, respectively, with a slight advantage with percutaneous access for shorter anesthesia time (191 vs 149 minutes), shorter procedure time (118 vs 98 minutes), and shorter median hospitalization (2 vs 1 days). Major blood loss (≥1000 mL) occurred in 2.0% (two of 98) of patients with cutdown. No (zero of 63) major blood loss was observed in patients with percutaneous access.

DISCUSSION

With the advent of EVAR, stent graft technology has evolved substantially over the past 2 decades. Most would agree that based on our current understanding, the ideal stent graft would go beyond the currently available devices in having the ability to accommodate the aortic neck for seal and provide fixation that can withstand the aortic forces and prevent migration and endoleaks. It would also have the ability for controlled, accurate positioning and deployment, and a low profile that could navigate through access vessels with significant tortuosity and calcifications and reduce device-related complications.

The Ovation stent graft is characterized by a trimodular design, with the aortic body composed of a low-permeability

Table V. Abdominal aortic aneurysm (AAA)-related secondary procedures through 1 year

Outcome	30 days % (n/N)	1 year % (n/N)
AAA-related secondary procedure ^a	1 (2/161)	6 (10/161)
Aortic body stenosis	0.0 (0/161)	2 (3/161)
Iliac limb occlusion	0.6 (1/161)	1 (2/161)
Iliac limb stenosis	0.6 (1/161)	0.6 (1/161)
Type Ia endoleak	0.0 (0/161)	1 (2/161)
Type Ib endoleak	0.0 (0/161)	0.6 (1/161)
Type II endoleak	0.0 (0/161)	2 (3/161)

^aTwo patients had one intervention to treat two outcomes.

PTFE graft with a suprarenal nitinol stent with anchors that provide active fixation. Unlike the previous stent grafts, the Ovation aortic body contains a network of inflatable sealing rings and channels that are filled with a low-viscosity radiopaque polymer during stent graft deployment. As the polymer cures in situ, it conforms to aortic necks of various shapes and provides proximal stent graft seal. The Ovation main body is delivered through a flexible hydrophilic-coated 14F OD catheter, the smallest profile of any currently commercially available stent graft. The Ovation iliac limbs are composed of highly flexible nitinol stents encapsulated in low-permeability PTFE that are packaged in low-profile 13F to 14F OD delivery systems that allow access in iliac arteries as small as 4.7 mm.

With these design characteristics, during the pivotal trial, the Ovation stent graft was implanted successfully in 100% of patients, and nearly 50% were treated percutaneously, without any access failures, type I or III endoleaks, stent graft migration, explant, or aneurysm rupture. Furthermore, at 1 year, the primary effectiveness end point of the study was achieved in 99% of the patients, with limited MAEs.

EVAR with the Ovation stent graft results in favorable outcomes compared with open surgery. The 1-year results of this study suggest favorable outcomes vs those reported for open surgery for several key variables,⁷ including all-cause mortality (3% vs 8%), AAA-related mortality (0.6% vs 3%), and, most notably, MAEs (6% vs 58%). These results with the Ovation stent graft also compare favorably with results of currently marketed stent grafts. In addition to 100% technical success, 1-year outcomes included only a 0.6% AAA-related mortality rate and a 0.6% AAA enlargement rate. With currently marketed stent grafts, technical success ranged from 97% to 100%, 1-year AAA-related mortality rate was 0% to 2%, and 1-year complication rates were 0% to 3% for type I endoleak, 0% to 7% for AAA enlargement, 0% to 2% for device migration, 0% to 1% for AAA rupture, and 0% to 2% for conversion to surgery.¹⁹⁻²³ The results of the current study also indicate that 39% of patients presented with aortoiliac anatomy that would be difficult to treat with currently available stent grafts.^{24,25} Furthermore, safety and effectiveness outcomes

were equally favorable in patients with typical or challenging anatomy.

One of the most common reasons for EVAR ineligibility is related to access. The Ovation stent graft accommodates access in ~90% of men and 70% of women with AAA, based on data from the Characterization of Human Aortic Anatomy Project.²⁶ In comparison, the minimum iliac diameter that can be accommodated with many other stent grafts is 6 mm, which allows access in only ~70% of men and 40% of women. Even in patients with challenging anatomy, the Ovation stent graft yielded excellent results, including 100% technical success, 97% freedom from MAEs through 1 year, and 3.2% freedom from MAEs with AAA-related secondary procedures. The Ovation stent graft has the ability to treat a wider range of patients compared with other stent grafts, especially those with narrow access vessels and short proximal necks, without sacrificing patient safety or device effectiveness.

Type II endoleaks were identified in 34% of patients at the 1-year follow-up visit. This endoleak rate, although higher than anticipated, is within the typically reported range²⁷ and may be partly due to the stringent CT protocol that recommended a maximum slice thickness of 2 mm. The median type II endoleak volume at 1 year was only 1 mL. For comparison, the mean volume of type II endoleaks that undergo intervention is 7 mL, whereas those that require no intervention average 4 mL.²⁸ Given the positive relationship between endoleak volume and aneurysm wall pressure,²⁹ these small type II endoleaks may portend a benign clinical course. The long-term trajectory of these endoleaks will be monitored and remains to be determined as patients undergo regular surveillance annually for 5 years under the study protocol.

The strengths of this trial included a large sample size, excellent generalizability attributable to enrollment at 36 sites in three countries, and stringent data collection, monitoring, and review methods following a common prospective protocol.

This study also had several limitations worth noting. First, this was a noncontrolled study, and therefore, comparative performance of the Ovation stent graft with alternative AAA treatments cannot be directly evaluated. Second, that women comprised 20 of 161 enrolled patients (12%) and that the mean maximum aneurysm diameter was 5.4 cm may be viewed as a limitation and may have biased the results in a favorable manner. A final study limitation is that the durability of the Ovation stent graft is not yet established beyond 1 year. Additional study will be required to elucidate long-term outcomes.

CONCLUSIONS

The 1-year outcomes with the Ovation stent graft are promising, with excellent demonstrated safety and effectiveness in patients with AAA. These results were similarly remarkable in patients with challenging anatomic characteristics who would be ineligible for treatment with other approved stent grafts. The Ovation stent graft may help to expand the patient population eligible for

endovascular aortic repair by accommodating a wider range of aortoiliac anatomies.

We thank Larry Miller, PhD, for providing research and editorial assistance and critical review and Tami Crabtree, MS, for providing statistical support.

AUTHOR CONTRIBUTIONS

Conception and design: MM, FV, TN

Analysis and interpretation: MM, FV, TN, GM, WJ, BG, ME, CB

Data collection: MM, FV, TN, GM, WJ, BG, ME, CB

Writing the article: MM

Critical revision of the article: MM

Final approval of the article: MM, FV, TN, GM, WJ, BG, ME, CB

Statistical analysis: Not applicable

Obtained funding: Not applicable

Overall responsibility: MM

REFERENCES

- Brewster DC, Cronenwett JL, Hallett JW Jr, Johnston KW, Krupski WC, Matsumura JS. Guidelines for the treatment of abdominal aortic aneurysms. Report of a subcommittee of the Joint Council of the American Association for Vascular Surgery and Society for Vascular Surgery. *J Vasc Surg* 2003;37:1106-17.
- Greenhalgh RM, Brown LC, Powell JT, Thompson SG, Epstein D, Sculpher MJ. Endovascular versus open repair of abdominal aortic aneurysm. *N Engl J Med* 2010;362:1863-71.
- Lederle FA, Freischlag JA, Kyriakides TC, Padberg FT Jr, Matsumura JS, Kohler TR, et al. Outcomes following endovascular vs open repair of abdominal aortic aneurysm: a randomized trial. *JAMA* 2009;302:1535-42.
- Agency for Healthcare Research and Quality. Healthcare Cost and Utilization Project (HCUP). Available at: <http://www.ahrq.gov/data/hcup/>. Accessed September 26, 2012.
- Matsumura JS, Brewster DC, Makaroun MS, Naftel DC. A multicenter controlled clinical trial of open versus endovascular treatment of abdominal aortic aneurysm. *J Vasc Surg* 2003;37:262-71.
- Greenberg RK, Chuter TA, Sternbergh WC 3rd, Fearnot NE. Zenith AAA endovascular graft: intermediate-term results of the US multicenter trial. *J Vasc Surg* 2004;39:1209-18.
- Turnbull IC, Criado FJ, Sanchez L, Sadek M, Malik R, Ellozy SH, et al. Five-year results for the Talent enhanced Low Profile System abdominal stent graft pivotal trial including early and long-term safety and efficacy. *J Vasc Surg* 2010;51:537-44. 44.e1-2.
- Carpenter JP. Multicenter trial of the PowerLink bifurcated system for endovascular aortic aneurysm repair. *J Vasc Surg* 2002;36:1129-37.
- Zarins CK, White RA, Schwarten D, Kinney E, Diethrich EB, Hodgson KJ, et al. AneuRx stent graft versus open surgical repair of abdominal aortic aneurysms: multicenter prospective clinical trial. *J Vasc Surg* 1999;29:292-305; discussion: 306-8.
- Makaroun MS, Tucheck M, Massop D, Henretta J, Rhee R, Buckley C, et al. One year outcomes of the United States regulatory trial of the Endurant Stent Graft System. *J Vasc Surg* 2011;54:601-8.
- Arko FR, Filis KA, Seidel SA, Gonzalez J, Lingle SJ, Webb R, et al. How many patients with infrarenal aneurysms are candidates for endovascular repair? The Northern California experience. *J Endovasc Ther* 2004;11:33-40.
- Armon MP, Yusuf SW, Latief K, Whitaker SC, Gregson RH, Wenham PW, et al. Anatomical suitability of abdominal aortic aneurysms for endovascular repair. *Br J Surg* 1997;84:178-80.
- Carpenter JP, Baum RA, Barker CF, Golden MA, Mitchell ME, Velazquez OC, et al. Impact of exclusion criteria on patient selection for endovascular abdominal aortic aneurysm repair. *J Vasc Surg* 2001;34:1050-4.
- Elkouri S, Martelli E, Gloviczki P, McKusick MA, Panneton JM, Andrews JC, et al. Most patients with abdominal aortic aneurysm are not suitable for endovascular repair using currently approved bifurcated stent-grafts. *Vasc Endovascular Surg* 2004;38:401-12.
- Moise MA, Woo EY, Velazquez OC, Fairman RM, Golden MA, Mitchell ME, et al. Barriers to endovascular aortic aneurysm repair: past experience and implications for future device development. *Vasc Endovascular Surg* 2006;40:197-203.
- Schumacher H, Eckstein HH, Kallinowski F, Allenberg JR. Morphometry and classification in abdominal aortic aneurysms: patient selection for endovascular and open surgery. *J Endovasc Surg* 1997;4:39-44.
- Mehta M, Byrne WJ, Robinson H, Roddy SP, Paty PS, Kreienberg PB, et al. Women derive less benefit from elective endovascular aneurysm repair than men. *J Vasc Surg* 2010;55:906-13.
- Agresti A, Coull B. Approximate is better than 'exact' for interval estimation of binomial proportions. *Am Stat* 1998;52:119-26.
- Food and Drug Administration. Summary of Safety and Effectiveness Data (SSED): EXCLUDER Bifurcated Endoprosthesis. 2002. Available at: http://www.accessdata.fda.gov/cdrh_docs/pdf2/P020004b.pdf. Accessed September 26, 2012.
- Food and Drug Administration. Summary of Safety and Effectiveness Data (SSED): Zenith AAA Endovascular Graft. 2003. Available at: http://www.accessdata.fda.gov/cdrh_docs/pdf2/P020018b.pdf. Accessed September 26, 2012.
- Food and Drug Administration. Summary of Safety and Effectiveness Data (SSED): Powerlink System. 2004. Available at: http://www.accessdata.fda.gov/cdrh_docs/pdf4/P040002b.pdf. Accessed September 26, 2012.
- Food and Drug Administration. Summary of Safety and Effectiveness Data (SSED): Talent Abdominal Stent Graft System. 2008. Available at: http://www.accessdata.fda.gov/cdrh_docs/pdf7/P070027b.pdf. Accessed September 26, 2012.
- Food and Drug Administration. Summary of Safety and Effectiveness Data (SSED): Endurant Stent Graft System. 2010. Available at: http://www.accessdata.fda.gov/cdrh_docs/pdf10/P100021b.pdf. Accessed September 26, 2012.
- Choke E, Munneke G, Morgan R, Belli AM, Loftus I, McFarland R, et al. Outcomes of endovascular abdominal aortic aneurysm repair in patients with hostile neck anatomy. *Cardiovasc Intervent Radiol* 2006;29:975-80.
- Murray D, Ghosh J, Khwaja N, Murphy MO, Baguneid MS, Walker MG. Access for endovascular aneurysm repair. *J Endovasc Ther* 2006;13:754-61.
- Sweet MP, Fillingner MF, Morrison TM, Abel D. The influence of gender and aortic aneurysm size on eligibility for endovascular abdominal aortic aneurysm repair. *J Vasc Surg* 2011;54:931-7.
- Veith FJ, Baum RA, Ohki T, Amor M, Adisesiah M, Blankensteijn JD, et al. Nature and significance of endoleaks and endotension: summary of opinions expressed at an international conference. *J Vasc Surg* 2002;35:1029-35.
- Keedy AW, Yeh BM, Kohr JR, Hiramoto JS, Schneider DB, Breiman RS. Evaluation of potential outcome predictors in type II Endoleak: a retrospective study with CT angiography feature analysis. *AJR Am J Roentgenol* 2011;197:234-40.
- Timaran CH, Ohki T, Veith FJ, Lipsitz EC, Gargiulo NJ 3rd, Rhee SJ, et al. Influence of type II endoleak volume on aneurysm wall pressure and distribution in an experimental model. *J Vasc Surg* 2005;41:657-63.

Submitted Sep 26, 2012; accepted Jun 18, 2013.

Additional material for this article may be found online at www.jvascsurg.org.

SUPPLEMENTARY METHODS (online only).**Ovation endovascular aneurysm repair (EVAR)**

Procedural details. The endovascular procedures were performed in a dedicated surgical-angiography suite. Patients were routinely heparinized before the procedure. The Ovation stent graft was inserted using a bilateral transfemoral approach in all cases. The first step consisted of bilateral positioning of a 0.035-inch guidewire for the insertion of two 8F short introducer sheaths. A 5F pigtail catheter was then positioned immediately above the renal artery ostia, and intraoperative angiography was performed.

The stent graft delivery system was advanced contralaterally with the support of a 180-cm Amplatz stiff guidewire (Cook Medical, Bloomington, Ind). A craniocaudal projection was performed to identify the proximal radiopaque markers in the landing zone. The aortic body was then deployed using stent release knobs on the handle.

The fill polymer was mixed inside a dedicated kit by alternately depressing the two-syringe plunger for approximately 15 strokes. Next, the full syringe was connected to the fill polymer injection port on the catheter handle and the syringe plunger was injected into an auto injector that warmed and applied controlled pressure to the polymer to fill the ring network. After the fill polymer solidified within the sealing rings, the aortic body delivery catheter was disengaged from the fill polymer injection port and withdrawn from the vasculature.

The contralateral and ipsilateral iliac limbs were each deployed through iliac limb delivery catheters. A 180-cm Amplatz stiff wire was passed from the contralateral access site into the contralateral distal leg of the aortic body. The contralateral iliac limb was then advanced into position and deployed. The ipsilateral iliac limb delivery catheter was advanced over the guidewire and deployed.

After the procedure, anticoagulation was routinely antagonized with protamine sulfate.

Supplementary Table I (online only). Enrolling principal investigators and institutions in the Ovation United States (U.S.) Food and Drug Administration (FDA)-investigational device exemption study sorted in descending order of patient enrollment by country and, secondarily, by site

<i>Investigator</i>	<i>Institution</i>
U.S.	
Manish Mehta	The Vascular Group, PLLC, Albany, NY
Gregory Mishkel	Prairie Education and Research, Springfield, Ill
William Jordan	University of Alabama-Birmingham, Birmingham, Ala
Charles Botti	Riverside Methodist Hospital, Columbus, Ohio
Mark Eskandari	Northwestern Memorial Hospital, Chicago, Ill
Bruce Gray	Greenville Hospital System, Greenville, SC
Karthik Kasirajan	Emory University Hospital, Atlanta, Ga
Daniel Clair	Cleveland Clinic Foundation, Cleveland, Ohio
Adnan Rizvi	Abbott Northwestern Hospital, Minneapolis, Minn
Mohiuddin Cheema	Hartford Hospital, Hartford, Conn
John Henretta	Mission Hospital, Asheville, NC
Wesley S. Moore	UCLA Medical Center, Los Angeles, Calif
Stephen Motew	Forsythe Medical Center, Winston-Salem, NC
John Eidt	Central Arkansas Veterans Healthcare System, Little Rock, Ark
Brijeshwar Maini	Moffitt Heart Pinnacle Health, Wormsleyburg, Pa
Dipankar Mukherjee	INOVA Fairfax Hospital, Falls Church, Va
Charles Sternbergh	Ochsner Health Systems, New Orleans, La
Kim Hodgson	Southern Illinois University, Springfield, Ill
Ash Jain	Washington Hospital, Fremont, Calif
Douglas Jicha	Santa Rosa Memorial Hospital, Santa Rosa, Calif
Paul Jones	Mercy Hospital and Medical Center, Chicago, Ill
Heitham Hassoun	Methodist Hospital, Houston, Tex
Thomas Maldonado	NYU Hospitals Center, New York, NY
Marc H. Glickman	Vascular and Transplant Specialists, Norfolk, Va
Paul Haser	University of Medicine and Dentistry of New Jersey, Stratford, NJ
Zvonimir Krajcer	St. Luke's Episcopal Hospital, Houston, Tex
John Laird	UC Davis Vascular Center, Sacramento, Calif
Michel Makaroun	UPMC Shadyside Hospital, Pittsburgh, Pa
Germany	
Thomas Nolte	Herz- und Gefäßzentrum, Bad Bevensen
Hans Krankenberg	Univiersitäres Herz und Gefäßzentrum, Hamburg
Horst Sievert	Cardiovascular Center Frankfurt-Sankt Katherine, Frankfurt
Klaus Mathias	Klinikum Dortmund GmbH, Dortmund
Dierk Scheinert	Herzzentrum Leipzig, Leipzig
Giovanni Torsello	Sankt Franziskus Hospital, Münster
Jan Brunkwall	University Klinik Koln, Koln
Chile	
Francisco Valdés	Pontificia Universidad Catolica de Chile, Santiago

Supplementary Table II (online only). Inclusion and exclusion criteria for the Ovation United States (U.S.) Food and Drug Administration (FDA)-investigational device exemption study

Inclusion criteria

- Age \geq 18 years
- Male or nonpregnant female
- Patient has signed an Ethics Committee/Institutional Review Board-approved informed consent form
- Candidate for open surgery
- Infrarenal AAA
 - (1) \geq 5.0 cm in diameter,
 - (2) has increased in diameter by at least 0.5 cm in last 6 months, or
 - (3) maximum diameter $>$ 1.5 times that of adjacent nonaneurysmal segment
- Patent iliac or femoral arteries that allow endovascular access with the TriVascular AAA device
- Suitable nonaneurysmal proximal aortic neck length of \geq 7 mm inferior to the most distal renal artery ostium
- Suitable nonaneurysmal distal iliac artery length (seal zone) of \geq 10 mm with repair anticipated to preserve at least one hypogastric artery
- Suitable nonaneurysmal proximal aortic neck luminal diameter between 16 and 30 mm
- Suitable nonaneurysmal distal iliac luminal diameters between 8 and 20 mm
- Distance from the most distal renal artery to most superior internal iliac artery measurement \geq 13 cm
- Juxtarenal aortic neck angulation \leq 60° if proximal neck length is \geq 10 mm or \leq 45° if proximal neck length is $<$ 10 mm
- Willing to comply with all required follow-up examinations

Exclusion criteria

- Dissecting or acutely ruptured aneurysm
 - Concomitant thoracic aneurysm or dissection
 - Acute vascular injury
 - Need for emergent surgery
 - Mycotic aneurysm or active systemic infection
 - Unstable angina
 - Myocardial infarction or stroke in the past 6 months
 - Major surgical or interventional procedure planned \leq 30 days of the AAA procedure
 - Connective tissue disease (eg, Marfan or Ehlers-Danlos syndrome)
 - Bleeding disorder or history of refusing blood transfusions
 - Dialysis-dependent renal failure or baseline serum creatinine level $>$ 2.0 mg/dL
 - Hypersensitivity or contraindication to anticoagulation or contrast media
 - Allergy or intolerance to PTFE, polyethylene glycol-based polymers, fluorinated ethylene propylene, or nitinol
 - Body habitus hinders radiographic visualization of the aorta
 - Life expectancy $<$ 1 year
 - Participation in another investigational device or drug clinical trial
 - Medical, social, or psychological conditions that, in the opinion of the investigator, preclude patient from receiving the required procedures and evaluations
-

AAA, Abdominal aortic aneurysm; PTFE, polytetrafluoroethylene.