



# Two Cases of Popliteal Cystic Adventitial Disease Treated with Primary Stenting: Long-Term Results

Renato A. Mertens, Michel Bergoeing, Leopoldo Mariné, Francisco Vargas, Ignacio Torrealba, and Francisco Valdés, Santiago, Chile

The cystic adventitial disease of the popliteal artery is an uncommon cause of intermittent claudication in young patients. Several treatment options are available, oriented to either drainage of the cyst and/or arterial reconstruction. Endovascular techniques have been exceptionally used to treat this condition, with mixed results. We report 2 young claudicants treated with primary stenting with continuous 4- and 10-year symptomatic relief and arterial patency.

The cystic adventitial disease of the popliteal artery is an unusual cause of intermittent unilateral claudication on young patients<sup>1–3</sup> with most reports being isolated cases, small series, or multi-institutional series.<sup>3</sup> Until 2014, 587 cases were reported.<sup>4</sup> Although there appears to be consensus on the diagnosis and imaging of the lesions, several treatment options are described, including open or percutaneous drainage of the cyst<sup>5</sup> allowing full arterial lumen expansion and various forms of arterial reconstruction, including autologous or prosthetic bypass.<sup>1–4</sup> Probably an underreported 8% recurrence rate has been described in a complete review of the world literature.<sup>4</sup>

Endovascular techniques have been used infrequently to treat this condition, and reports consist mostly of cases of balloon angioplasty with or without stenting, with mixed or poor results.<sup>4–10</sup>

We reported our first case treated with stenting in 2013.<sup>11</sup> We now report long-term results for 2 patients.

## CASE REPORT

### Case 1

A healthy and active 36-year-old female, presented with recent onset of 300 meters right calf intermittent claudication. Ankle-brachial index (ABI) and PVR waveforms dropped during exertion protocol at 2.7 km/hr and 10% inclination, coincidental with claudication appearance. Blood test results were normal.

A computed tomography angiogram (Fig. 1) showed a localized right popliteal artery stenosis at the knee level in an otherwise normal vessel. A fluid collection in the arterial wall compressed the lumen, as seen in subadventitial cystic lesions.

Treatment options were discussed, and she requested a minimally invasive procedure to enable her to return quickly to her active lifestyle. Informed consent was obtained.

Selective right lower extremity angiography through the contralateral approach was obtained and confirmed the CTA findings. A 6 × 40 mm bare-metal, nitinol self-expanding not oversized stent was deployed at the lesion (Silver®, Cook Medical, Bloomington, IN). The immediate result was satisfactory, but a residual 20–30% stenosis was observed (Fig. 1). Balloon angioplasty was purposely not performed. She was discharged on dual antiplatelet treatment with aspirin 100 mg daily for life and clopidogrel 75 mg daily for 1 month.

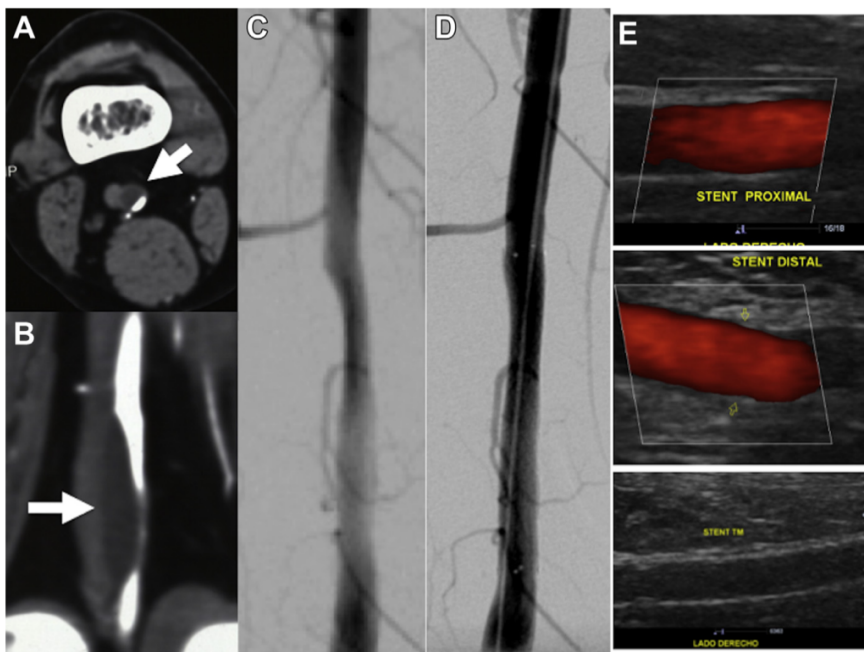
A strict follow-up protocol was initiated with clinical and duplex scan evaluations that were performed every 6 months for 2 years. CTA was obtained at 12 and 24 months and a duplex scan yearly (Fig. 1). Early claudi-

Departamento de Cirugía Vascular y Endovascular, Escuela de Medicina, Pontificia Universidad Católica de Chile, Santiago, Chile.

Correspondence to: Renato A. Mertens, MD, FACS, 3990 Apoquindo #601 Las Condes, Santiago, Chile; E-mail: [renatomertens@gmail.com](mailto:renatomertens@gmail.com)

*Ann Vasc Surg* 2020; 63: 460.e1–460.e4  
<https://doi.org/10.1016/j.avsg.2019.08.099>

© 2019 Elsevier Inc. All rights reserved.



**Fig. 1.** (A, B): Preintervention CT scan, the arrows point the cystic lesion. (C, D): Pre and post stenting angiography. (E): Late duplex scan followup showing full expansion of the stent and no cyst on longitudinal grayscale view.

stenosis were observed. The cystic lesion was not visible (Fig. 2). At 117 months of followup, the patient remains asymptomatic, and the stent fully patent.

### Case 2

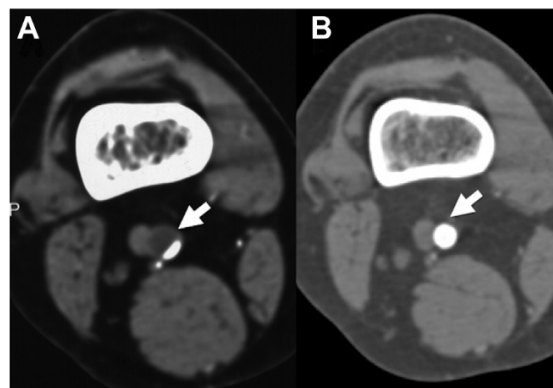
A healthy 53-year-old man, presented with recent onset of left calf intermittent claudication at 200 meters. His popliteal and distal pulses were absent on physical examination. The left ankle-brachial index was 0.44 at rest. Blood test results were normal.

A computed tomography angiogram (Fig. 3) showed a localized left popliteal artery stenosis at the knee level, in a relationship with a cystic lesion in the arterial wall.

A minimally invasive procedure was offered to the patient. Informed consent was obtained.

Selective left lower extremity angiography through the contralateral approach was obtained and confirmed the CTA findings. A 7 × 40 mm bare-metal, nitinol self-expanding and not oversized stent was deployed at the lesion (Misago®, Terumo Medical, Tokio, Japan). The immediate result showed a residual of 30–40% stenosis (Fig. 3). Balloon angioplasty was not performed. He was discharged on dual antiplatelet treatment with aspirin 100 mg daily for life and clopidogrel 75 mg daily for 6 months.

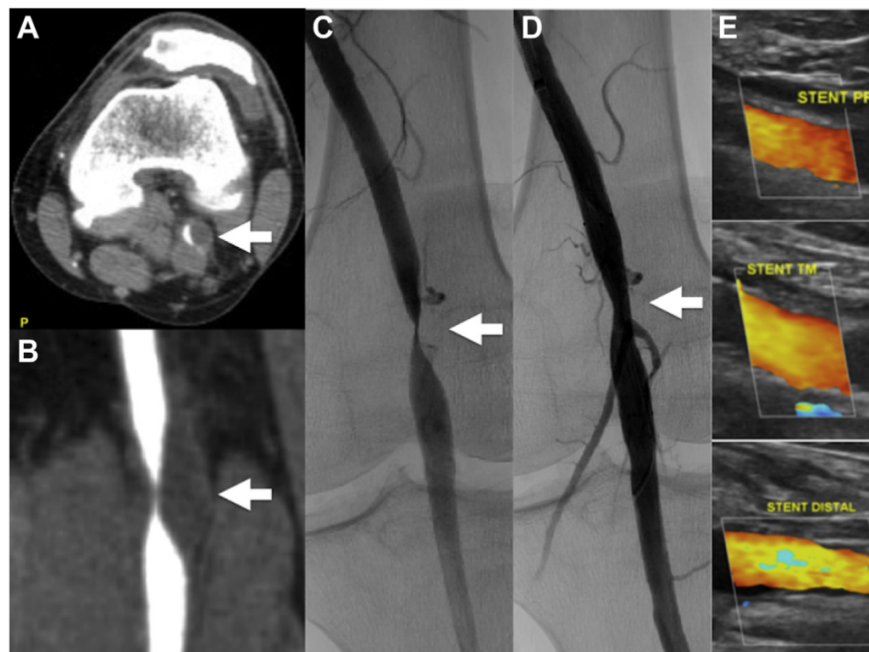
At a 1-month follow-up visit, he could walk 3 Km without claudication; pulse examination and ABI were normal. The duplex scan showed a fully expanded stent at 3 months and no signs of the cyst. At 51 months of followup, the patient remains asymptomatic, with the stent fully patent and no cystic formation seen on the duplex



**Fig. 2.** Axial reconstruction of an AngioCT scan before (A) and 24 months after stenting (B), showing complete expansion of the stent and resolution of the Cyst (arrows point at the cystic lesion and late full expansion of the stent).

### DISCUSSION

The cystic adventitial disease is an unusual lesion. Fluid accumulates subadventitally and compresses the lumen of the artery limiting distal flow. Considering the fact that the cyst's fluid is similar to synovial fluid, mostly located at the knee level and exceptionally described in other locations, the hypothesis of an anatomic relationship of the cyst with the knee joint has been raised. There is also



**Fig. 3.** (A, B): Pre-intervention CT scan, the arrows point the cystic lesion. (C, D): Pre and post stenting angiography. (E): Late followup duplex scan in longitudinal view showing full expansion of the stent and no visible cyst.

between these 2 structures in 17% of the cases.<sup>4,12</sup> MR imaging<sup>13</sup> and surgical findings<sup>14,15</sup> have demonstrated this, and it may be a cause for recurrence.

Intermittent claudication due to cystic adventitial disease is very uncommon and should be suspected in young, mostly male individuals. Critical ischemia is unusual, but thrombosis at the site of arterial stenosis has been described. Contrast-enhanced CT scan, nuclear magnetic resonance, and duplex ultrasound are imaging diagnostic tests.

Management has been mostly surgical,<sup>1,4</sup> with cyst drainage to allow expansion of the arterial lumen or arterial reconstruction with a bypass being the main option described. Results tend to favor the latter, but based only on case reports and small series. A minimally invasive approach has been described by percutaneous drainage of the cyst,<sup>5</sup> with mixed results.

Endovascular techniques have been seldom used, mostly balloon angioplasty<sup>6,8</sup> and as secondary interventions.<sup>4,6</sup>

Since the cyst is underneath the adventitia, it is reasonable to expect balloon angioplasty to fail. Unless the intima and media or the adventitia are disrupted and the content of the cyst is drained either into the artery or toward the periarterial space, the cystic lesion would otherwise remain unchanged

The idea behind deploying a bare-metal self-expanding stent, is allowing the stent's radial force to induce remodeling of the arterial wall, "pushing" the content of the cyst out of the adventitia, probably using the same connections described with the knee joint, collapsing the cystic cavity and probably inducing an inflammatory reaction to seal the cyst. It is impossible to prove this concept, but based on the knowledge from previous anatomic observations in the literature<sup>12–14</sup> and the fact that balloon angioplasty was not performed, avoiding the possible induction of intimal hyperplasia in these otherwise normal arteries, it likely seems to be a reasonable explanation for the excellent results seen in these 2 patients.

Stenting has been described with a stent graft associated to balloon angioplasty with early failure<sup>9</sup> and also as a secondary intervention for cyst recurrence after open surgery, using a bare-metal stent and obtaining long-term patency.<sup>6</sup>

Intimal hyperplasia induced by a rigid stent in a highly mobile artery is a major concern with this procedure. Probably avoiding the injury of balloon angioplasty and unnecessary oversizing of the stent in an otherwise normal artery could explain our good results in these 2 patients. Strict followup is warranted and timely secondary intervention when needed: probably a short vein bypass graft



Based on only 2 patients, it is not possible to make a general recommendation for this rare disease,<sup>16</sup> but primary stenting is a reasonable option if the patient agrees with a close follow up, avoiding or postponing a more invasive procedure.

## CONCLUSION

Primary stenting of cystic adventitial disease of the popliteal artery with a nonoversized, bare-metal, self-expanding nitinol stent is a reasonable alternative to open surgery in selected cases. As with other endovascular procedures, strict follow up is needed.

## REFERENCES

1. Baxter A, Garg K, Lamparello P, et al. Cystic adventitial disease of the popliteal artery: is there a consensus in management? *Vascular* 2011;19:163–6.
2. Tsolakis I, Walvatne C, Caldwell M. Cystic adventitial disease of the popliteal artery: diagnosis and treatment. *Eur J Vasc Endovasc Surg* 1998;15:188–94.
3. Motanganahalli R, Smeds M, Harlander-Locke M, et al. A multi-institutional experience in adventitial cystic disease. *J Vasc Surg* 2017;65:157–61.
4. Desy N, Spinner R. The etiology and management of cystic adventitial disease. *J Vasc Surg* 2014;60:235–45.
5. van Rutte P, Rouwet E, Belgers E, et al. In treatment of popliteal artery cystic adventitial disease, primary bypass graft not always first choice: two case reports and a review of the literature. *Eur J Vasc Endovasc Surg* 2011;42:347–54.
6. Maged J, Kron I, Hagspiel K. Recurrent cystic adventitial disease of the popliteal artery: successful treatment with percutaneous transluminal angioplasty. *Vasc Endovascular Surg* 2009;43:399–402.
7. Setacci F, Sirignano P, de Donato G, et al. Adventitial cystic disease of the popliteal artery: experience of a single vascular and endovascular center. *J Cardiovasc Surg (Torino)* 2008;49:235–9.
8. Khoury M. Failed angioplasty of a popliteal artery stenosis secondary to cystic adventitial disease: a case report. *Vasc Endovascular Surg* 2004;38:277–80.
9. Raj S, Davies R, Vohra R. Failure of endovascular stenting for popliteal cystic disease. *Ann Vasc Surg* 2009;23:410.e1–e5.
10. Fox R, Kahn M, Adler J, et al. Adventitial Cystic disease of the popliteal artery: failure of percutaneous transluminal angioplasty as a therapeutic modality. *J Vasc Surg* 1985;2:464–7.
11. Mertens R, Bergoeing M, Mariné L, et al. Endovascular treatment of cystic adventitial disease of the popliteal artery. *Ann Vasc Surg* 2013;27:1185.e1–e3.
12. Spinner R, Desy N, Agarwal G, et al. Evidence to support that adventitial cysts, analogous to intraneural ganglion cysts, are also joint-connected. *Clin Anat* 2013;26:267–81.
13. Maged I, Turba U, Housseini A, et al. High spatial resolution magnetic resonance imaging of cystic adventitial disease of the popliteal artery. *J Vasc Surg* 2010;51:471–4.
14. Tsilimparis N, Hanack U, Yousefi S, et al. Cystic adventitial disease of the popliteal artery: an argument for the developmental theory. *J Vasc Surg* 2007;45:1249–52.
15. Cassar K, Engeset J. Cystic adventitial disease: a trap for the unwary. *Eur J Vasc Endovasc Surg* 2005;29:93–6.
16. Mertens R. Innovation in rare diseases, is it possible, or do we have to continue “copying and pasting”? *Angiología* 2014;66:225–6.

